ORIGINAL ARTICLE
10

J Turk Spinal Surg 2025;36(1):10-16
DOI: 10.4274/jtss.galenos.2024.68553

RISK FACTORS CONTRIBUTING TO SYMPTOMATIC ADJACENT SEGMENT DISEASE FOLLOWING LONG-SEGMENT POSTERIOR INSTRUMENTATION WITH PELVIC SCREWS IN DEGENERATIVE SPINE DISEASE: A RETROSPECTIVE COHORT ANALYSIS

Yiğit Kültür, Mehmet Nuri Erdem

İstanbul Yeni Yüzyıl University Faculty of Medicine, Department of Ortopaedics and Traumatology, İstanbul, Türkiye

ABSTRACT

Objective: Adjacent segment disease (ASD) is a complication commonly associated with spinal instrumentation; it usually requires further surgery and deteriorates the quality of life of patients. Although many studies have been conducted regarding the risk factors of ASD in short-segment surgeries, the literature regarding long-segment posterior instrumentation with pelvic screws and transforaminal lumbar interbody fusion is limited. Therefore, this study evaluated the incidence, cause, and outcome of ASD in such cases.

Materials and Methods: This retrospective study included 127 patients who underwent long-segment posterior instrumentation between January 2010 and December 2017. Among them, 15 developed symptomatic ASD requiring revision surgery. The diagnostic criteria encompassed >20% intervertebral disc height reduction, >5° angulation on flexion-extension X-rays, >3 mm sagittal translation, and facet joint degeneration.

Results: The overall revision rate was 11%. The median follow-up duration was 107 months, with mean of 114±23 months. There were 9 females and 6 males in the ASD cohort, with a mean age of 65.7±5.3 years, compared with a mean age of 62.9±7.6 years for non-ASD patients. The most common level for ASD to occur was T9-10 ($p<0.05$). Advanced age, degenerative changes, and the absence of vertebroplasty or cemented screws had a significant contribution.

Conclusion: ASD is a significant complication of long-segment posterior instrumentation. The strategy for identifying high-risk patients, particularly by modifiable factors like age >65, smoking, and determination of the upper instrumented vertebra, has important implications for prevention. Prophylactic vertebroplasty and use of cemented screws may reduce ASD risk.

Keywords: Spine, lumbar vertebrae, sakrum, spinal fusion

INTRODUCTION

Long-segment posterior spinal instrumentation is a standard surgical technique that pertains specifically to the treatment of degenerative spinal disorders. Although this surgical technique was effective in the acquisition of both stability and fusion of the spine, it usually presented several complications[1]. The most frequent complication was the occurrence of adjacent segment disease (ASD), which is characterized by degeneration in the segments adjacent to the fused segments[2]. ASD generally presents itself as painful instability and, in many instances, requires additional surgery.

ASD significantly impacts the patient outcome, an impact that is manifested as a reduction of quality of life. Further, the necessity of secondary surgical procedures raises the healthcare expenditure. The risk factors known to contribute to the development of ASD are many; they include advanced age, pre-existing degenerative changes, and extension and length of the fusion[3]. Thus, the question of whether ASD represents an inevitable consequence of long-segment fusion or can be avoided by surgical technique remains controversial despite the available literature. Although many studies have demonstrated various risk factors for ASD after one- or two-level spinal surgeries, clinical research related to the outcomes and risk factors of long-segment spinal fixation with pelvic

Address for Correspondence: Yiğit Kültür, İstanbul Yeni Yüzyıl University Faculty of Medicine, Department of Ortopaedics and Traumatology, İstanbul, Türkiye
E-mail: yigitkulturr@hotmail.com
ORCID ID: orcid.org/0000-0001-8201-6994
Received: 11.12.2024 **Accepted:** 19.12.2024 **Epub:** 30.12.2024 **Publication Date:** 22.01.2025
Cite this article as: Kültür M. Erdem MN. Risk factors contributing to symptomatic adjacent segment disease following long-segment posterior instrumentation with pelvic screws in degenerative spine disease: a retrospective cohort analysis. J Turk Spinal Surg. 2025;36(1):10-16. [Epub Ahead of Print]

©Copyright 2025 The Author. Published by Galenos Publishing House on behalf of Turkish Spine Society.
This is an open access article under the Creative Commons Attribution-NonCommercial-NoDerivatives 4.0 (CC BY-NC-ND) International License.

screws combined with transforaminal lumbar interbody fusion is still very rare[4-6].

This retrospective study determines the incidence of, risk factors governing, and clinical outcome for ASD in patients undergoing long-segment posterior spinal instrumentation. More precisely, it looks into the added benefit provided by a number of newer surgical techniques-upper instrumented vertebra (UIV) selection, vertebroplasty at the proximal levels of instrumentation, and cement-augmented screw application-in mitigating ASD risk. This study is designed to better the long-term outcomes for patients and reduce the incidence of this difficult complication by pinpointing modifiable risk factors and implementing appropriate preventive measures.

MATERIALS AND METHODS

Study Population Selection

This series retrospectively studied those patients who underwent long-segment posterior spinal instrumentation combined with transforaminal lumbar interbody fusion between January 2010 and December 2017. The spine center represents a catchment area of about fifteen million people and carries out more than 150 spinal deformity surgeries annually. The participants all provided their informed consent, and this study has been approved by the Institutional Review Board at our institution. The study was approved by the İstanbul Yeni Yüzyıl University of Local Ethics Committee (approval number: 2024/10-1346, date: 15.10.2024). A total of 127 patients were involved; however, only 15 symptomatic ASD patients who underwent revision surgery comprised the series. The T8 was measured as UIV in 2 participants, T9 in 55, T10 in 46, L1 in 11, and L2 in 13. In this study, interest lay in proximal ASD, taking into consideration the fact that all the subjects underwent sacral and iliac fixation to perform the needed spinopelvic stabilization. In those patients who received vertebroplasty, treatments were performed in the most proximal two instrumented vertebrae and the vertebra above the level of instrumentation (Figure 1). Data were collected regarding demographic information, the surgical methods utilized, and radiographic follow-through.

The criteria for diagnosing symptomatic ASD were appearance of new patterns of pain after the surgery, which were related to patient symptoms, and correlated with radiological evidence of adjacent segment degeneration. Radiographic assessment included standing AP and lateral spine radiographs taken pre-operatively, post-operatively, and during the follow-up period. Dynamic flexion-extension radiographs were included in the pre-operative examination. The investigations also included magnetic resonance imaging (MRI) and computed tomography scans, which were taken pre-operatively and at the final follow-up.

Inclusion Criteria

Patients with long-segment posterior spinal instrumentation-e.g., a minimum of 5 levels for primary degenerative spinal pathologies, where the UIV are at L2 or proximal, with fixation using sacral and iliac screws. The presence of adequate imaging for pre-operative and post-operative radiographic evaluation. Patients received at least one MRI study in the post-operative period.

Exclusion Criteria

Patients presenting with spinal infection, neoplasm, or trauma. Patients with severe neurological deficits post-operatively.

Radiographic Assessment

Standardized radiographic criteria for the development of ASD included dynamic lateral flexion-extension X-ray and standing AP and lateral spine X-ray. Standardized pre-operative and

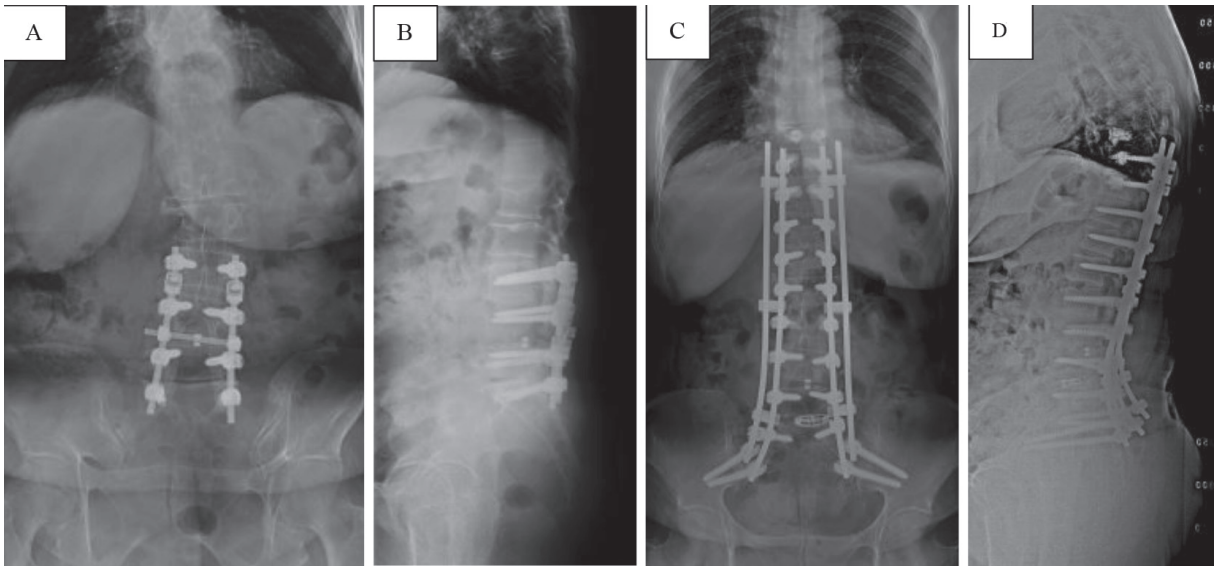

Figure 1. Pre-operative (A, B) and post-operative (C, D) X-rays of T10-iliac posterior instrumentation case with the use of cemented screws and vertebroplasty

immediate post-operative X-ray were obtained. X-rays were also performed at each follow-up. MRI were taken in all patients pre-operatively and last follow-up. The following parameters were measured to detect radiographic evidence of ASD:

• Disc height reduction: Decrease of more than 20% in intervertebral disc height at the adjacent segment compared to the immediate post-operative X-ray[7].

• Degenerative changes in the facet joints: According to Weishaupt classification[8], increase by one or more grades was considered the development of ASD.

• Anterior and/or posterior osteophyte formation: New formation or marked growth of osteophytes (more than 3 mm) at the adjacent level was accepted as a sign of ASD[9].

• Sclerosis or subchondral bone changes, thickening and hardening or cystic, may be seen in vertebral endplates adjacent to the fusion.

• Range of motion evaluation: Assessed using dynamic flexion-extension X-rays to detect hypermobility (defined as an angular motion increase of more than 5° compared to the pre-operative measurements) at the adjacent segment[10].

• Adjacent segment instability: A translation of >3 mm on dynamic sagittal lateral X-ray is considered instability[9].

In particular, all radiographic assessments were made separately by two blinded spine surgeon, and a consensus of ASD diagnosis was attained. In the case of any detection of disagreement, then an independent third assessment was performed by radiologist.

Surgical Intervention

In all instances in this series, long-segment posterior spinal instrumentation with pelvic screw fixation was carried out. All the surgeries were done through a standard midline posterior approach under general anesthesia. Multilevel decompression with fusion was carried out as per the pathology, and transforaminal lumbar interbody fusion was added if necessary for additional segmental stabilization.

Surgeries consisted of extension of instrumentation proximally to the degenerated segment. Laminectomy with decompression was performed in 12 of 15 ASD patients due to radiologically obvious hypertrophic ligamentum flavum, stenosis, and facet hypertrophy causing compression of the spinal cord.

Extension of instrumentation proximally was undertaken in the presence of radiological evidence of instability of the adjacent segment, degeneration, or extension of deformity. Vertebroplasty and cemented screw was performed in selected cases to avoid ASD.

The follow-up was done according to a routine monitoring schedule at 1 month, 6 months, and a year, with standing anteroposterior and lateral X-ray, for the study of the stability of the adjacent segments.

RESULTS

This series includes 127 patients who underwent long-segment posterior spinal instrumentation (Table 1). In follow-up, symptomatic ASD developed in 15 patients (11.8%), while the remaining 112 patients (88.2%) did not have any signs of ASD. The cohort consisted of 72 males (56.7%) and 55 females (43.3%). The mean age for the entire patient population was 63.2±7.4 years. Comparatively, marked differences were registered for ASD and non-ASD patients. Patients from the ASD group were older at 65.7±5.3 years compared to those from the non-ASD group, who were younger at 62.9±7.6 years. Although this difference did indicate a trend for the possible risk factor of older age in the development of ASD, it did not attain statistical significance at p=0.14. It was thus noted that a larger number of patients over 65 years were well represented in the ASD group, thus making age an important factor to be considered while assessing the risk for ASD. The range of follow-up was from 73 to 155 months, with a median of 107 months and an average of 114±23 months. The mean BMI for all patients was 28.7±4.1. The mean BMI for the ASD group was 29.2±4.5 and

Table 1. Flowchart of the study group

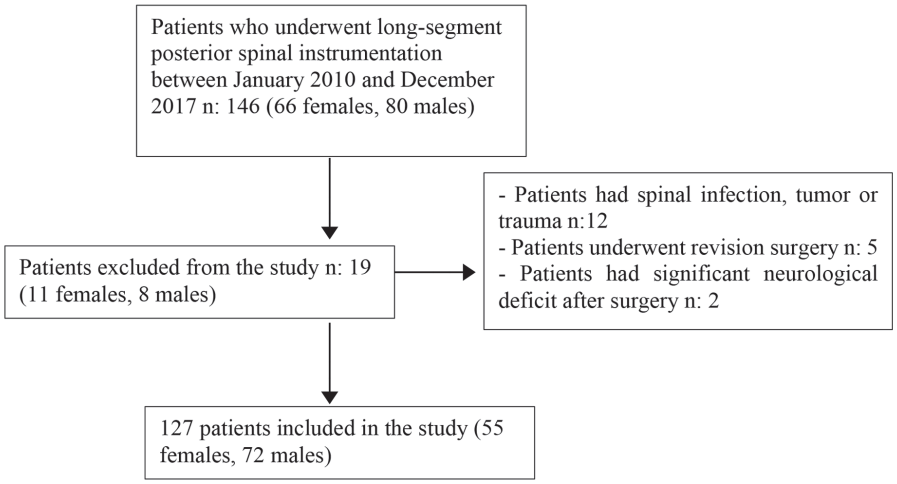

for the non-ASD group was 28.5±4.0. However, this was not statistically significant (p=0.21). Diabetes mellitus: 33.1%, that is, 42 patients of the overall cohort had DM. In the ASD group, 40% which constitutes 6 patients, were diagnosed to have DM, while 32.1%, that is, 36 patients, had DM in the non-ASD group. DM was not statistically different between the groups (p=0.45). However, smoking was higher in the ASD group. Though 43.3% of all the patients were smokers, comprising 55 patients, this was as high as 66.7% among the ASD group, comprising 10 patients as opposed to 40.2%, comprising 45 patients in the non-ASD group. The difference was statistically significant, (p=0.03*), implying that smoking may thus have contributed to the development of ASD as shown in Table 2.

In the radiographic measurements, there were no significant differences between groups regarding sagittal vertical axis; C7 plumb line-central sacral vertical line, sacral slope, lumbar lordosis, pelvic tilt, and coronal Cobb angle during pre-operation and at the final follow-up (Table 3).

Of the ASD patients in the ASD group, the majority were located at the T9-10 level with a total of 9 patients; 4 presented ASD at T8-9; 1 presented at T12-L1 and 1 at L1-L2. All patients had only proximal ASD. All the cases of ASD were treated as cases of symptomatic degeneration by reoperation to extend the instrumentation. In 12 patients, radiologically evident hypertrophic ligamentum flavum with adjacent segment stenosis and facet hypertrophy causing spinal cord compression was seen, hence, laminectomy with decompression was performed to relieve the compression (Table 4). Risk factor analysis revealed that advanced age strongly correlated with pre-existing degenerative spinal changes (Table 5). In ASD, patients with fusions extending to T10 had a significantly higher incidence as compared to others (p<0.05).

Vertebroplasty was utilized markedly less in the ASD group compared with the non-ASD group (p<0.05). The use of cemented screws was noted to be applied with considerably lower frequency within the ASD cohort compared to those with no ASD status in all cases at (p<0.05).

Statistical Analysis

Data analysis was conducted using SPSS software. The distribution of continuous variables were tested by Shapiro-Wilk. Normally distributed variables were described as mean ± standard deviation, and non-normally distributed variables as median. Besides, the results of categorical variables, including presence of upper level vertebroplasty and cemented screws, were expressed as frequency and percentage.

Comparisons for subjects with ASD versus subjects without ASD were done using the following tests:

Table 2. Demographic characteristics

Characteristics	All patients (n=127)	ASD group (n=15)	Non-ASD group (n=112)	p-value
Age (mean ± SD)	63.2±7.4	65.7±5.3	62.9±7.6	0.14
Gender (male/female)	72/55	6/9	66/46	0.22
BMI (mean ± SD)	28.7±4.1	29.2±4.5	28.5±4.0	0.21
Diabetes mellitus (%)	42 (33.1%)	6 (40%)	36 (32.1%)	0.45
Smoking (%)	55 (43.3%)	10 (66.7%)	45 (40.2%)	0.03*

ASD: Adjacent segment disease, SD: Standard deviation, BMI: Body mass index

Table 3. Radiographic analysis between groups in terms of SS, LL, PT, and coronal Cobb angle

Parameter	T10 group (n=9)	T9 group (n=4)	L1 group (n=1)	L2 group (n=1)	p-value
SVA pre-op	78.4 (-25-137)	70.2 (-30-140)	75.8 (-20-135)	73.0 (-28-130)	0.5842
SVA final follow-up	59.3 (-9-158)	61.2 (-12-155)	58.8 (-10-160)	62.5 (-11-162)	0.5920
C7PL-CSVL pre-op	14.2 (0-90)	15.0 (1-92)	13.5 (0-88)	14.8 (1-89)	0.2153
C7PL-CSVL final follow-up	9.2 (0-39)	10.0 (0-42)	8.5 (0-37)	9.8 (0-40)	0.7684
Pre-op LL	33.8±19.5	34.5±18.2	32.6±15.0	31.9±14.5	0.680
Last follow-up LL	36.2±13.4	37.0±12.5	39.1±10.9	38.6±10.4	0.230
Pre-op PI	44.1±10.2	45.7±11.0	47.9±9.9	49.0±10.5	0.045
Last follow-up PI	47.4±13.8	47.9±13.4	49.6±8.8	50.2±8.3	0.490
Pre-op PT	18.8±8.7	20.2±8.6	22.4±9.1	22.9±9.3	0.090
Last follow-up PT	15.5±10.1	15.0±6.5	16.1±6.0	15.8±6.2	0.980
Pre-op SS	25.9±9.1	26.5±9.0	27.1±8.9	27.4±9.1	0.740
Last follow-up SS	31.9±10.2	32.7±10.0	34.1±7.8	34.6±7.9	0.200
Pre-op Cobb	10.9±5.1	10.3±5.4	9.5±5.1	10.0±5.3	0.330
Last follow-up Cobb	4.8±2.4	5.1±2.6	5.3±2.8	5.6±2.7	0.190

SVA: Sagittal vertical axis, C7PL-CSVL: C7 plumb line-central sacral vertical line, SS: Sacral slope, LL: Lumbar lordosis, PT: Pelvic tilt

Table 4. Surgical technique of 1st operation, time to 2nd operation and surgical detail of 2nd operation

Case	Sex	Age	1st operation	Time to 2nd operation (months)	2nd operation
1	F	75	TLIF L4-5, L5-S1 (T9-iliac screws)	23	Instrumentation
2	M	72	TLIF L4-5 (T10-iliac screws)	24	Instrumentation
3	F	69	TLIF L3-4, 4-5 (T9-iliac screws)	26	Instrumentation+laminectomy
4	F	68	TLIF L4-5 (T10-iliac screws)	30	Instrumentation+laminectomy
5	M	71	TLIF L3-4, L5-S1 (T9-iliac screws)	32	Instrumentation+laminectomy
6	F	57	TLIF L4-5 (L1-iliac screws)	33	Instrumentation+laminectomy
7	M	60	TLIF L5-S1 (T10-iliac screws)	35	Instrumentation+laminectomy
8	F	61	TLIF L3-4 (T10-iliac screws)	33	Instrumentation+laminectomy
9	F	72	TLIF L4-5 (L2-iliac screws)	38	Instrumentation+laminectomy
10	M	55	TLIF L4-5 (T10-iliac screws)	40	Instrumentation+laminectomy
11	F	68	TLIF L4-5, L5-S1 (T10-iliac screws)	41	Instrumentation+laminectomy
12	M	61	TLIF L3-4 (T9-iliac screws)	42	Instrumentation+laminectomy
13	F	68	TLIF L5-S1 (T10-iliac screws)	36	Instrumentation
14	M	67	TLIF L4-5 (T10-iliac screws)	27	Instrumentation+laminectomy
15	F	71	TLIF L4-5, L5-S1 (T10-iliac screws)	29	Instrumentation+laminectomy

TLIF: Transforaminal lumbar interbody fusion, F: Female, M: Male

Table 5. Risk factors for ASD development

Risk factors	ASD group (n=15)	Non-ASD group (n=112)	p-value	Odds ratio	95% CI
Age (>65)	10 (66.7%)	28 (25.0%)	0.01*	3.50	1.35-9.08
Pre-operative degenerative changes	12 (80.0%)	40 (35.7%)	<0.01**	4.67	1.70-12.82
Vertebroplasty	3 (20.0%)	56 (50.0%)	0.02*	0.28	0.08-0.93
Cemented screw use	4 (26.7%)	60 (53.6%)	0.03*	0.33	0.10-1.00

*p<0.05 and **p<0.01 indicate significant differences, ASD: Adjacent segment disease, CI: Confidence interval

Independent Samples t-test: This is used to compare the mean of normally distributed continuous variables between groups.

The Mann-Whitney U test was performed for follow-up duration-a continuous variable with a non-normal distribution.

Chi-square (χ^2) test: In comparisons of categorically distributed variables, including proportion of patients with vertebroplasty or cemented screw placement in ASD versus non-ASD subjects. Fisher's exact test if expected count in contingency table for categorical variables were less than 5.

Multivariate logistic regression analysis was done to elucidate predictive factors in the development of ASD based on the following independent variables: Age, pre-existing degenerative spinal changes, the use of vertebroplasty, and cemented screws. The Hosmer-Lemeshow test was used to evaluate the goodness-of-fit for this regression model.

A probability value less than 0.05 was taken as the level of significance. The adjusted odds ratios and 95% confidence intervals of each risk factor involved were measured in the logistic regression analysis.

DISCUSSION

We therefore conducted the study to determine the incidence, risk factors, and outcome of symptomatic ASD after long-segment posterior spinal instrumentation with pelvic screws in patients with degenerative spine disease. In the series, the incidence of ASD was 11.8%, showing a high clinical impact of the complication. Advanced age, smoking, pre-operative degenerative spinal changes, and selection of the UIV were critical risk factors for ASD. The use of cemented screws and vertebroplasty also seemed to play a protective role against ASD. Based on our observation of a considerable incidence of ASD in the surgical cases performed during the initial years commencing from 2010, targeted prevention strategies were implemented. These included the performance of vertebroplasty on the non-instrumented vertebra adjacent to the proximal end of instrumentation and usage of cemented screws. As we initiated these, the rates of ASD began to dramatically decline; as such, we made them a standard for all cases beyond 2015. Beside, based on the authors' experience, adequate bending of

the rod at the UIV may potentially reduce the risk of ASD. That would be one way intrinsically to decrease mechanical stress at the junction between instrumented and non-instrumented segments while maintaining the biomechanical essence of the spinal column.

We thus studied our cases retrospectively and compared the two groups in an attempt to measure the impact of this prevention on the rate of ASD. These findings add to the literature in targeting the risk factors that influence ASD and, once again, highlight how important careful pre-operative planning and surgical strategy are in avoiding this complication.

Kimura et al.[1] studied the risk of ASD and distal junctional failure in patients who underwent long-segment spinal fusion ending at L5. They concluded that there was an increased risk of ASD and distal junctional failure for those patients, especially when the UIV were at the thoracic levels of T7-T10. Thus, our investigation demonstrated that the precise extent of the proximal end of spinal fusion significantly contributed to the creation of ASD and pointed out that advanced age and pre-operative degenerative changes were important risk factors. These findings stress the importance of segment selection in the process of surgical planning.

Ma et al.[3] performed a study to determine the risk factors related to post-operative ASD after multi-level posterior lumbar interbody fusion. They found that one of the pre-operative factors was a Pfirrmann grade ⩾3, high pelvic incidence, and an increased number of decompressed levels were the only significant determinants in ASD development. They reported the protective effect of cemented screws and vertebroplasty in reducing the risk of ASD. Such findings have brought into view the importance of addressing modifiable risk factors in the prevention of ASD.

Pinto et al.[11] pointed out the main contribution of the surgical methodology itself, such as the type of interbody fusion, the extension of the fusion construct, and sagittal alignment restoration, to the development of ASD. They also realized how cardinal the determinants are because of the surgical approach and anatomical dissection.

Glattes et al.[12] evaluated the incidence and consequence of proximal junctional kyphosis in adults following extended posterior spine fusion. The incidence of ASD was 26%. Interestingly, development of ASD did not result in any adverse consequence in terms of SRS-24 scores or sagittal alignment, and did not identify any patient or radiographic variable that could predispose to it. Pehlivanoğlu et al.[13] report that the most common causes of revision surgery following the surgical treatment of adult spinal deformity are severe sagittal malalignment and proximal junctional kyphosis. They stressed that these situations can be prevented by not missing the proximal fusion levels to the thoracolumbar junction rather than T10 and not using PMMA-augmented screws in patients with osteoporosis during surgical planning. In this framework, our research designates the importance of accurate surgical planning, with an especial focus on the role of the UIV and techniques such as cement-augmented screws in reducing ASD and further need for revision surgery.

Puvanesarajah et al.[14] investigated factors associated with revision surgery after long-segment fusion for adult spinal deformity in elderly patients. In this respect, it was discovered that osteoporosis drastically enhanced the risk of revision surgeries while bone morphogenetic protein application had a protective effect. Other critical factors affecting the outcomes could be smoking and instrumentation failure. Similarly, in our study, ASD was more frequent among patients who smoked.

Quinn et al.[15] emphasised that ASD may occur in all types of spine surgery; the consequence of a constellation of post-operative mechanical factors superimposed upon natural aging of the spine. Such technical contributors to ASD highlighted from the authors are represented by laminectomy adjacent to a fusion and also a failure to restore appropriate segmental lordosis. It also provided that ASD is often prone to significantly impact functional outcome and usually requires surgical revision in cases of severe refractory back pain or neurological deficit. As evolution in newer concepts took place, such as minimally invasive techniques and motion preservation, it has clearly failed to show any reduction in the incidence of ASD. Conclusively, their findings highlight the importance of restoration of global, regional, and segmental alignment, in addition to decompression and stabilization, while planning surgery for the treatment of ASD.

The research has certain limitations that need to be acknowledged. First, without the pre-operative DEXA studies of the bone density, there is every possibility that the associated factors of osteoporosis may have underestimated the definition of ASD. Secondly, the nature of the study was retrospective. Thus, the conclusions regarding causality are limited due to reliance on previously collected data, which is subject to various biases: selection and recall biases. Lastly, the number of symptomatic ASD patients was small, and this may limit the generalisability of the results.

CONCLUSION

ASD following long-segment posterior spinal instrumentation in adult degenerative spines is a common complication with significant clinical and quality-of-life implications. Evaluating high-risk patients based on factors such as age >65, smoking, pre-operative degenerative changes, and the selection of the fusion levels may help mitigate this risk. The use of cemented screws and prophylactic vertebroplasty are effective surgical techniques for reducing the risk of ASD. Further research is needed to develop surgical techniques and preventive strategies aimed at reducing ASD incidence and improving long-term patient outcomes.

Ethics

Ethics Committee Approval: The study was approved by the İstanbul Yeni Yüzyıl University of Local Ethics Committee (approval number: 2024/10-1346, date: 15.10.2024).

Informed Consent: Informed consent was obtained from all participants in this study.

Acknowledgments

The authors would like to thank the secretary, Mr. Emre Mert, for his considerable help in sorting through the archives that had some challenges and difficulties. It is hereby confirmed that Mr. Emre Mert has given his approval to have his name printed in the Acknowledgments section.

Footnotes

Authorship Contributions

Surgical and Medical Practices: Y.K., M.N.E., Concept: Y.K., M.N.E., Design: Y.K., M.N.E., Data Collection or Processing: Y.K., Analysis or Interpretation: Y.K., M.N.E., Literature Search: Y.K., M.N.E., Writing: Y.K., M.N.E.

Conflict of Interest: No conflict of interest was declared by the authors.

Financial Disclosure: The authors declared that this study received no financial support.

REFERENCES

1. Kimura R, Hongo M, Abe E, Kobayashi, T, Kikuchi, K, Kinoshita H, et al. Adjacent segment disease after long spinal fusion ending at L5 for adult spinal deformity: a retrospective cohort study. Open J Orthop. 2022;12:268-76.
2. Jagadeesh NH, Bansal K, Chhab HS. Adjacent segment disease: current evidence and the role of motion preservation technologies. Indian Spine J. 2023;6:3-14.
3. Ma Z, Huang S, Sun J, Li F, Sun J, Pi G. Risk factors for upper adjacent segment degeneration after multi-level posterior lumbar spinal fusion surgery. J Orthop Surg Res. 2019;14:89.
4. Sato S, Yagi M, Machida M, Yasuda A, Konomi T, Miyake A, et al. Reoperation rate and risk factors of elective spinal surgery for degenerative spondylolisthesis: minimum 5-year follow-up. Spine J. 2015;15:1536-44.
5. Chen Y, Zhou Y, Chen J, Luo Y, Wang Y, Fan X. A systematic review and meta-analysis of risk factors for reoperation after degenerative lumbar spondylolisthesis surgery. BMC Surg. 2023;23:192.
6. Bydon M, Alvi MA, Goyal A. Degenerative lumbar spondylolisthesis: definition, natural history, conservative management, and surgical treatment. Neurosurg Clin N Am. 2019;30:299-304.
7. Wang G, Hu J, Liu X, Cao Y. Surgical treatments for degenerative lumbar scoliosis: a meta analysis. Eur Spine J. 2015;24:1792-9.
8. Weishaupt D, Zanetti M, Boos N, Hodler J. MR imaging and CT in osteoarthritis of the lumbar facet joints. Skeletal Radiol. 1999;25:215-9.
9. Hilibrand AS, Robbins M. Adjacent segment degeneration and adjacent segment disease: the consequences of spinal fusion? Spine J. 2004;4:190-4.
10. Ushio S, Hirai T, Yoshii T, Inose H, Yuasa M, Kawabata S, et al. Preoperative risk factors for adjacent segment degeneration after two-level floating posterior fusion at L3-L5. Spine Surg Relat Res. 2020;4:43-9.
11. Pinto EM, Teixeira A, Frada R, Atilano P, Miranda A. Surgical risk factors associated with the development of adjacent segment pathology in the lumbar spine. EFORT Open Rev. 2021;6:966-72.
12. Glattes RC, Bridwell KH, Lenke LG, Kim YJ, Rinella A, Edwards C 2nd. Proximal junctional kyphosis in adult spinal deformity following long instrumented posterior spinal fusion: incidence, outcomes, and risk factor analysis. Spine (Phila Pa 1976). 2005;30:1643-9.
13. Pehlivanoğlu T, Akgül T, Bayram S, Sarıyılmaz K, Dikici F, Talu U. Prognostic criteria for post-operative success in patients undergoing surgery for adult spinal deformities. J Turk Spinal Surg. 2021;32:131-7.
14. Puvanesarajah V, Shen FH, Cancienne JM, Novicoff WM, Jain A, Shimer AL, et al. Risk factors for revision surgery following primary adult spinal deformity surgery in patients 65 years and older. J Neurosurg Spine. 2016;25:486-93.
15. Quinn JC, Buchholz AL, Buell T, Haid R, Bess S, Lafage V, et al. Adjacent segment disease after lumbar spine surgery-part 2: prevention and treatment. Contemp Neurosurg. 2018;40:1-8.