Research Square

Preprints are preliminary reports that have not undergone peer review.
They should not be considered conclusive, used to inform clinical practice,
or referenced by the media as validated information.

Anatomical variations of the zygomaticofacial foramen and its related canal through the zygomatico-orbital and zygomaticotemporal foramina in dry human skulls

Gkionoul Nteli Chatzioglou (gkionoul.chatzioglou@istun.edu.tr)
Istanbul Health and Technology University
Latif Sağlam
Istanbul University
Buse Naz Çandır
Istanbul Yeni Yüzyıl University
Mehmet Yiğit
Istanbul University
Özcan Gayretli
Istanbul University

Research Article

Keywords: zygomaticofacial foramen, zygomatic bone, zygomatico-orbital foramen, zygomaticotemporal foramen, malar bone

Posted Date: April 19th, 2023

DOI: https://doi.org/10.21203/rs.3.rs-2814564/v1

License: This work is licensed under a Creative Commons Attribution 4.0 International License. Read Full License

Additional Declarations: No competing interests reported.

Version of Record: A version of this preprint was published at Surgical and Radiologic Anatomy on December 13th, 2023. See the published version at https://doi.org/10.1007/s00276-023-03257-x.

Abstract

Purpose

The aim of this study is to reveal the location of the zygomaticofacial foramina, the variations of their numbers, and their connections between the zygomatico-orbital and zygomaticotemporal foramina.

Methods

Ethics committee approval of our study was received by the Istanbul Medical Faculty Clinical Research Ethics Committee (date:30.07.2021, number:358356). 171 zygomatic bones of unknown gender from the Department of Anatomy, Istanbul University, were included in this study. The number of zygomaticofacial foramen and their connections with the zygomatico-orbital foramen and the zygomaticotemporal foramina were examined. Also, the morphometric distances between the zygomaticofacial foramen were calculated. Evaluation of the data was done with SPPS v.21.

Results

The number of zygomaticofacial foramina was found as 299. It was found single, double, three, four, five and six foramina, in 52 (30.4%), 52 (30.4%), 24 (14.03%), 10 (5.85%), 5 (2.93%), 1 (0.58%) zygomatic bone, respectively. Zygomaticofacial foramen was absent in 27 (15.8%) bones. Of these 299 foramina, 129 were found to be connected with zygomatico-orbital foramen and 23 with zygomaticotemporal foramen. It was noted that 147 zygomaticofacial foramina had no connection with any foramina. The distances between the zygomaticofacial foramen and the frontozygomatic suture, temporal process, maxillary process, the lowest point of the zygomatic bone, and orbital rim were found as 25.30 ± 2.81mm, 18.74 ± 3.56mm, 21.56 ± 4.16mm, 18.72 ± 2.57mm, 6.67 ± 3.27mm, respectively.

Conclusion

Consequently, the location and variations of ZFF are of great importance for maxillofacial surgery and regional block anesthesia. Knowing its location and variations will help prevent complications during any surgical intervention in this region.

Introduction

While the zygomatic bone of humans is known as malar bone-cheekbone or zygoma, in most reptiles, amphibians, and birds are called jugal bone and represents a skull bone. In humans, the zygoma is also of aesthetic significance for facial appearance, and its restoration following trauma has resulted in a large clinical literature [1]. The zygoma connects the midfacial and cranial skeletons as it is a crucial part of the craniofacial skeleton. This connection is essential for comprehending evolutionary relationships since the masseter muscle and numerous other facial muscles have been thought to be an important buttress of the viscerocranium bone for resisting masticatory stresses [2].

The zygomatic (malar, cheek) bones are two small, quadrangular bones situated at the upper and outer part of the face. They form the prominence of the cheek, part of the outer wall and floor of the orbit, and part of the temporal and zygomatic fossa. Each bone has four processes (the frontal, orbital, maxillary, and zygomatic) and four borders (antero-superior or orbital, antero-inferior or maxillary, postero-superior or temporal, postero-inferior or zygomatic). Also, each bone presents for examination external (malar) and internal surfaces. The *malar surface* is smooth convex, perforated near its center by one or two small openings called zygomaticofacial foramina. On the other hand, the *internal surface*, directed backward and inward, is concave, presenting internally a rough, triangular surface, for articulation with the maxillary bone: and externally, a smooth concave surface, which above forms the anterior boundary of the temporal fossa, and below, where it is wider, forms part of the zygomatic fossa. This surface presents, above its center, the aperture of one or two zygomatic canals, and affords attachment to a portion of the masseter muscle at its lower part.

The zygomatic bone contains several small openings including the zygomaticofacial foramen (ZFF), zygomatico-orbital foramen (ZOF) and zygomaticotemporal foramen (ZTF), which serve as exit sites for respective branches of the maxillary nerve (V2). Although the existence of these foramina is well documented, their frequency and exact position can vary significantly among different individuals and between the complementary halves of the zygomatic bones in an individual [3]. Variations in the frequency and location of the zygomatic foramina are important for the success of maxillofacial and orbital procedures, which involve osteotomies across the zygoma [4, 5]. The exact position of the zygomatic bone is critical as it is one of the important components that must be dealt with during face surgery. The ZFF on the malar surface of the bone is where the zygomaticofacial nerve and vessels emerge.

The zygomaticofacial nerve is a branch of a terminal branch of the zygomatic nerve that is divided from the maxillary division of the trigeminal nerve. It supplies the skin of the cheek and pierces the orbicularis oculi muscle. It unites the branches of the face and maxillary nerves to form a plexus. The nerve and the foramen may occasionally be absent [2]. The ZFF may serve as a helpful anatomical landmark for determining the depth of facial dissection close to the bone, according to several publications [4, 6, 7]. During facial surgery, the zygomatic nerve and its branches may be damaged in the periorbital region [5, 8]. Blind surgical dissections in this region have the potential to rupture the arteries coming from the ZFF, leading to postoperative hematoma [9]. Numerous instances of osteotomies in the malar region have resulted in zygomaticofacial nerve damage. Stretching the nerve might be able to prevent numbness in the malar region [9–11]. Elevating the periorbita from the lateral wall has the potential to rupture the zygomaticofacial arteries, thus it's critical to locate them and coagulate them to stop bleeding, avulsion, and other postoperative hematoma problems. The presence and variations of the zygomaticofacial nerve, vessels, and foramina may influence the success of surgery [5–9, 11, 12]. The success of maxillofacial and orbital treatments, which include osteotomies across the zygoma, depends on variations in the number and distribution of the zygomatic foramina [4, 5]. A method called orbitozygomatic osteotomy is utilized to reveal vascular and cancerous lesions near the base of the skull, according to recent publications [13–15]. The orbitozygomatic osteotomy requires five incisions to release the zygomatic bone in one piece above the zygomaticofacial foramen [15]. In addition, Gronul et al [16] emphasized the necessity of

protecting significant neurovascular systems in the zygomatic region during transmaxillary surgical approaches to the orbit. This procedure is used to remove infraorbital tumors and has been shown to be preferable to the transcranial approach as it is less invasive and produces more aesthetically pleasing results [16]. The location and occurrence of the ZFF are described in a few papers [2, 4, 5, 11]. However, the zygomatic bone exhibits differences in the number of foramina. An anthropological marker for identifying individuals and races is the frequency of its occurrence [5, 12]. This study examined dried skulls from Anatolian populations to determine the frequency, distribution, the number of ZFF as well as the connections between the ZFO and ZTF through a canal.

Metarial And Methods

Ethics committee approval of our study was received by the XXXXXXXX Medical Faculty Clinical Research Ethics Committee (date: 30.07.2021, number: 358356). 171 zygomatic bones, whose sex was unknown, in the Department of Anatomy, Istanbul University, were included in the study. Regarding the zygomaticofacial foramen, the following morphological evaluations and morphometric measurements were included in our study.

The morphological measurements were as follows:

1. The number of zygomaticofacial foramina were detected.
2. The regional placement of the ZFFs according to the four regions were determined.
   To determine the position of the ZFF, two lines (vertical and transverse) from the malar surface of the zygomatic bone were used. The first (vertical) line was drawn from the frontozygomatic suture to the lowest point of the zygomaticomaxillary suture, and the second (transverse) line was between the point where the angle formed by the frontal and temporal process and the inferior wall of the orbit medially. The location of the zygomaticofacial foramina according to the Inferomedial (A), Inferolateral (B), Superolateral (C), and Superomedial (D) regions of the malar surface of zygomatic bone were determined (Fig. 1).
3. The connections of ZFF with ZOF and ZTF were examined.

   To detect the connections between the ZFF and ZOF, a thin wire was passed through the ZFF, and it was observed and recorded whether it came out of the ZOF and ZTF. A fine acupuncture needle (0.20x13mm) was used.
4. The connections of ZFFs with ZOF and ZTF were examined according to the four regions. When there were multiple foramina, the largest was considered "main," and all of the following described morphometric measurements were taken accordingly.

   The morphometric measurements were as follows (Fig. 2):

   1- The distance between ZFF and frontozygomatic suture (ZFF-FS)

   2- The distance between ZFF and temporal process of zygomatic bone (ZFF-TP)

   3- The distance between ZFF and maxillary process of zygomatic bone (ZFF-MP)

   4- The distance between the ZFF and the lowest point of the zygomatic bone (ZFF-LP)

   7- The distance between ZFF and the orbital rim was measured (ZFF-OR)

   A digital caliper with 0.01mm precision (Mitutoyo Company, Kawasaki-shi, Kanagawa, Japan) was used for morphometric measurements. The evaluation of the data was performed by SPPS v.21. Since the zygomatic bones didn't belong to the same individual, a statistical correlation between the sides couldn't take into consideration.

Results

The number of ZFF was found to be 141 (47%) on the right side and 158 (53%) on the left side. Single ZFF in 52 bones (30.4%), double ZFF in 52 bones (30.4%), three ZFFs in 24 bones (14.03%), four ZFFs in 10 bones (5.85%), five (2.93%) in 5 bones and six ZFFs in 1 bone (0.58%) were observed. The ZFF was absent in 27 bones (15.8%) (Table 1 and Fig. 3). The location of ZFF according to the regions were seen that the region C was the most commonly located, and the region D the least. The frequency of the most common placement of ZFF by regions was 41.47% (C region), 30.77% (B region), 27.42% (A region) and 0.34% (D region), respectively.

Table 1
The number and proportions of the zygomaticofacial foramina (ZFF) according to the sides (right-left).

Number of zygomaticofacial foramen in each bone	Absecnt (0) zygomaticofacial foramen	Single (1) zygomaticofacial foramen	Double (2) zygomaticofacial foramen	Three (3) zygomaticofacial foramen	Four (4) zygomaticofacial foramen	Five (5) zygomaticofacial foramen	Six (6) zygomatic foramen
Right	13	35	27	10	3	2	0
Left	14	17	25	14	7	3	1
Total number of zygomaticofacial foramina	0	52	104	72	40	25	6

It was observed that 152 of 299 ZFFs detected in our study were connected with ZOF or ZTF via a canal. It was noted that 147 ZFF had no connection with any foramina. 129 of 152 ZFFs were found to be associated with ZOF and 23 were connected with ZTF (Table 2). The results of these connections according to the four regions were examined. It was seen that 57 of 82 ZFFs at region A were associated with ZOF, while the remaining 25 ZFFs did not show any connection with the ZTF. In addition, 34 of the 92 ZFFs at region B were associated with ZOF and 4 were associated with ZTF. Nevertheless, it was discovered that the remaining 54 ZFFs had no connections to either ZOF or ZTF. At region C, the 37 of 124 ZFFs were connected via canal with ZOF and the 19 ZFFs with ZTF. The remaining 68 ZFFs did not show any connection with any foramina. Finally, the only ZFF seen at the region D was seen to be connected with ZOF (Table 3).

Table 2
The number of connections between the zygomaticofacial foramen and zygomatico-orbital (ZFF-ZOF), and between the zygomaticofacial and zygomaticotemporal foramen (ZFF-ZTF) according to the sides (right and left).

Number of connections of ZFF-ZOF and ZFF-ZTF	Right	Left	Total
Connections of ZFF-ZOF	71/141	58/158	129/299
Connections of ZFF-ZTF	8/141	15/158	24/299
Absent connection	63/141	84/158	146/299

Table 3
The number of connections between the zygomaticofacial foramen and zygomatico-orbital (ZFF-ZOF), and between the zygomaticofacial and zygomaticotemporal foramen (ZFF-ZTF) according to the regions (A, B, C, D) and sides (right and left).

	Sides	Regions of external surface of the zygomatic bone				Total
Number of connections of ZFF-ZOF and ZFF-ZTF		A	B	C	D	
Connections of ZFF-ZOF	Right	32	17	21	1	71
	Left	25	17	16	0	58
Connections of ZFF-ZTF	Right	0	4	4	0	8
	Left	0	0	15	0	15
Absent connection	Right	10	22	31	0	63
	Left	15	32	37	0	84
Total		82	92	124	1	299

The findings of the morphometric results obtained for the ZFF-FS, ZFF-TP, ZFF-MP, ZFF-LP, and ZFF-OR were found as 25.30 ± 2.81 mm, 18.74 ± 3.56mm, 21.56 ± 4.16mm, 18.72 ± 2.57mm, 6.67 ± 3.27mm, respectively. The findings of these morphometric measurements according to the regions (A, B, C, D) are given in Table 4.

Table 4
Mean ± standard deviation (SD), minimum, maximum values of morphometric parameters according to zygomaticofacial foramen. In case of multiple foramina, the resluts between the distances of the largest - main zygomaticofacial foramen (ZFF) and the frontozygomatic suture (FS), temporal process of zygomatic bone (TP), maxillary process of zygomatic bone (MP), lowest point of the of the zygomaticomaxillary suture (LP), orbital rim (OR).

		REGIONS OF EXTERNAL SURFACE OF THE ZYGOMATIC BONE			
		A	B	C	D
The number of the largest ('main') zygomaticofacial foramina		70	76	96	1
ZFF-FS (mm)	Mean ± SD	25.65 ± 2.60	25.97 ± 2.52	24.67 ± 2.74	27.36
	Minimum	19.57	20.62	17.9	-
	Maximum	32.56	32.56	30.6	-
ZFF-TP (mm)	Mean ± SD	19.07 ± 2.66	19.00 ± 2.10	18.51 ± 2.63	20.90
	Minimum	11.35	13.25	11.35	-
	Maximum	26.06	25.02	26,06	-
ZFF-MP (mm)	Mean ± SD	21.14 ± 3.15	21.49 ± 2.74	22.00 ± 2.73	18.99
	Minimum	13.55	13.55	14.91	-
	Maximum	29.53	30.59	28.73	-
ZFF-LP (mm)	Mean ± SD	18.42 ± 3.16	18.21 ± 2.33	19.27 ± 2.42	20.23
	Minimum	12.43	12.75	12.43	-
	Maximum	26.51	23.74	28.72	-
ZFF-OR (mm)	Mean ± SD	6.42 ± 1.26	6.98 ± 1.68	6.52 ± 1.70	6.10
	Minimum	4.72	4.45	3.25	-
	Maximum	11.9	16.34	11.76	-

The results of the morphometric values according to the regions, it was discovered that the ZFF located at the region D had the greatest ZFF-FS and ZFF-TP values, while the region C had the lowest. The ZFF-MP value was highest at the region C and lowest at region D; similarly, the ZFF-LP parameter was highest at region D and lowest at region B. Finally, region B had the greatest ZFF-OR value while region D had the lowest (Table 4).

Discussion

There may be one or three ossification centers in the zygomatic bone. They appear in the eighth week of pregnancy and fuse in the 22nd [5]. The embryological origin of the variations, as well as the high number of ZFF, could be related to the number of ossification centers. Although ZFF has been reported as single, double, triple, quadruple, or 5 foramina according to the literature [4, 5, 11, 12, 17], it has also been reported as absent occasionally. In our study, ZFF with 6 foramina was detected in a single zygomatic bone, which has not been defined before in the literature, except for the foramina of the ZFF seen between 0–5. Aksu et al [17] have found five zygomaticofacial foramina on 2 sides (1.3%) in their anatomical study of the morphological and morphometric varieties of the ZFF. Similarly, we found five foramina on 5 sides (1.67%) in this study.

The average incidence of ZFF in the literature varies between 0.9 and 2.2, according to the foramina index [18–20]. It is seen that the findings of our study regarding the incidence of ZFF are similar to the results of Kim et al [20].

However, possible explanations for the absence of the zygomaticofacial nerve in the absence of ZFF have been reported in the literature [5]. In this case, the other branches of the trigeminal nerve anastomose with the zygomaticofacial nerve and provide sensory innervation of the malar skin [4, 5]. This may help to explain why, if the nerve is severed during surgery, sensory innervation may still exist.[5] It might also be the result of a congenital nerve deficiency. In the reported studies, the frequency of absence of ZFF has been reported to vary between 10% and 21.8% [4, 5, 11, 12, 17–20]. In our study, this rate was found to be 15.8%. It is debatable whether the zygomaticofacial nerve and its associated artery, a branch of the lacrimal artery [21–23], or the nerve itself are lodged in the zygomatic canal [24, 25]. The zygomaticofacial foramina could not exist in all skulls, which could be explained by the possibility that this nerve is occasionally absent [26]. The infraorbital or zygomaticofacial nerves may invade the area of supply in such circumstances. The likelihood that the nerve crosses the inferior orbital edge after penetrating the orbital septum in those without foramina can only be hypothesized. During facial surgery, the relationship between the ZFF and the frontozygomatic suture is critical. The location of the ZFF is also important during zygomatic fracture stabilization, which involves the placement of screws above the zygomaticofrontal suture [27]. According to Martins et al [4] and Aksu et al [17], the ZFF is 2.5–2.6 cm from the zygomaticofrontal suture and 0.6–0.7 cm from the inferolateral orbital rim (the closest inferolateral orbital angle from the main ZFF center). Our data is consistent with Martins' and Aksu's findings [4, 17]. The distance of ZF-FZ ranged between 24-27mm [4, 11, 17, 28], between these values similar results have been found (25.30 ± 2.81 mm) in our study. Our result of the ZFF-OR parameter was similar to the data of Aksu et al [17], while in the literature ZFF-OR ranged between 2.5–8.05mm [4, 11, 17, 28]. In this study, the average distance of ZF-ZMS was found to be 18.72 ± 2.57 mm similar to the data of Aksu et [17] and less similar to the results of Lone et al [28]. This knowledge may be useful in locating the ZFF during minimally surgical intervention. The most inferior zone point was selected as the ZFF during the orbitozygomatic osteotomy [6, 7].

The zygomatic bone ossifies generally from three centers, which appear about the eight weeks. One for the zygomatic and two for orbital portion, and fuse about the fifth month of the fetal life. The bone is sometimes, after birth, seen to be divided by a horizontal suture into an upper and larger and a lower and smaller division. In some quadrumana the malar bone consists of two parts, and orbital and a malar, which are ossified by separate centers. The zygomatic bone can occasionally be divided in half by a vertical or a horizontal suture. Due to its frequent observation in Japanese populations, this type of bipartite bone has been given the name *os Japonicum* (os Ainoicum) [29–31]. Where the zygomatic bone and temporal bone converge to form the zygomatic arch, a sutural bone may be visible. In our study, variations like bipartite have not been observed. The length between the ZFF and the zygomaticotemporal suture and the distance between the ZFF and zygomaticotemporal suture (ZFF-TP) and the distance between the ZFF and the zygomaticomaxillary suture (ZFF-MP) were calculated as 18.74 ± 3.56 mm and 21.56 ± 4.16 mm, respectively. In a case of bipartite zygomatic bone reported by Nikolova et al [32], the ZFF-TP and ZFF-MP parameters were found to be 19.13 mm and 25.51 mm, respectively.

In terms of regional distribution of the foramina, approximately half of them were located at region C in this study (124 foramina, 41.47%). These results were similar to the findings of Lone et al [28] and Aksu et al [17]. The only difference was the rate of region D, where Lone et al [28] has not been reported any foramina at region D. We believed that this difference is due to number samples and population difference between our study. The regional location of ZFF according to the connections with the ZOF and ZTF were analyzed which have not been reported before in the literature. The ZFFs which did not represent any connection and those who showed connection with ZTF were found mostly at region C while the ZFF which connected with ZOF were mostly located at region A (Table 3). Therefore, we have observed that the ZFF may vary depending on its connections in the determination of danger zones.

According to this study, considering the regional location of the ZFF, the region C should be approached more carefully, especially in osteotomy procedures for zygomatic bones. However, where ZFF is associated with ZOF, the danger zone appears to be region A. Therefore, it is seen that much more care should be taken in invasive procedures for these two regions. It could be argued that region D, which has a lesser ZFF distribution (0.34%), is a better choice for surgery.

Declarations

Ethical Approval

Ethics committee approval of our study was received by the Istanbul Medical Faculty Clinical Research Ethics Committee (date: 30.07.2021, number: 358356).

Competing interests

The authors declare that they have no conflict of interest

Authors' contributions

G.N.C., L.S. wrote the main manuscript text and B.N.C., M.Y. and O.G. prepared figures 1-3 and tables. All authors reviewed the manuscript

Funding

No funding received

Availability of data and materials

gkionoul.chatzioglou@istun.edu.tr

References

1. Kelly CP, Cohen AJ, Yavuzer R, Jackson IT (2005) Cranial bone grafting for orbital reconstruction: is it still the best? J Craniofac Surg 16:181–185.
2. Standring S. Gray's anatomy: the anatomical basis of clinical practice. 41st ed. Elsevier Health Sciences 2016.
3. Chanda A, Nanda A (2002) Anatomical study of the orbitozygomatic transsellar transcavernous—transclinoidal approach to the basilar artery bifurcation. J Neurosurg 97:151–160.
4. Martins C, Li X, Rhoton Jr AL (2003) Role of the zygomaticofacial foramen in the orbitozygomatic craniotomy: anatomic report. Neurosurg 53:168–173.
5. Mangal A, Choudhry R, Tuli A, Choudhry S, Khera V (2004) Incidence and morphological study of zygomaticofacial and zygomatico-orbital foramina in dry adult human skulls: the non-metrical variants. Surg Radiol Anat 26:96–99.
6. Aziz KM, Froelich SC, Cohen PL, Sanan A, Keller JT, van Loveren HR (2002) The one-piece orbitozygomatic approach: The Mac- Carty burr hole and the inferior orbital fissure as keys to technique and application. Acta Neurochir 144:15–24.
7. Gonzalez LF, Crawford NR, Horgan M, Deshmukh P, Zammbranski JM, Spetzler RF (2002) Working area and angle of attack in three cranial base approaches: Pterional, orbitozygomatic and maxillary extension of the orbitozygomatic approach. Neurosurg 96:144–149.
8. Lei T, Gao JH, Xu DC, Zhong SZ, Li XJ, Chen B, Yang DY, Wang XH (2006) The frontal-temporal nerve triangle: A new concept of locating the motor and sensory nerves in upper third of the face rhytidectomy. Plast Reconstr Surg 117:385–394.
9. Williams JV (2002) Transblepharoblasty endoscopic subperiostal midface lift. Plast Reconstr Surg 110:1769–1775.
10. Newman J (2006) Safety and efficacy of midface-lifts with an absorbable soft tissue suspension device. Arch Facial Plast Surg 8:245–251.
11. Hwang SH, Jin S, Hwang K (2007) Location of the zygomaticofacial foramen related to malar reduction. J Craniofac Surg 18:872–874.

12. Jose RG, Dahinten S, Hernandez M (2001) The settlement of patagonia: A matrix correlation study. Hum Biol 73:233–248.
13. Keyser AW (2000) The Drimolen skull: The most complete Australopithecine cranium and mandible to date. S Afr J Sci 96:189–193.
14. Hollier LH, Thornton J, Pazmino P, Stal S (2003) The management of orbitozygomatic fractures. Plast Reconstr Surg 111:2386–2392.
15. van Furth WR, Agur AMR, Woolridge N, Cusimano MD (2005) The orbitozygomatic approach. Neurosurg 58:103–7.
16. Gronul E, Erdogan E, Duz B, Timurkaynak E (2003) Transmaxillary approach of the orbit: An anatomical study. Neurosurg 53:935–42.
17. Aksu F, Ceri NG, Arman C, Zeybek FG, Tetik S (2009) Location and incidence of the zygomaticofacial foramen: an anatomic study. Clinic Anat 22:559–562.
18. Loukas M, Owens DG, Tubbs RS, Spentzouris G, Elochukwu A, Jordan R (2008) Zygomaticofacial, zygomaticoorbital and zygomaticotemporal foramina: anatomical study. Anat Sci Int 83:77–82.
19. Kim HJ, Paik DJ, Choi BY, Chung MS, Han SH, Hwang YI, Koh KS (1997) Measurements of the zygomatic bones and morphology of the zygomaticofacial and zygomaticotemporal foramina in Korean. Korean J Phys Anthropol 10:225–234.
20. Kim HS, Oh JH, Choi DY, Lee JG, Choi JH, Hu KS, Yang HM (2013) Three-dimensional courses of zygomaticofacial and zygomaticotemporal canals using micro-computed tomography in Korean. J Craniofac Surg 24:1565–1568.
21. Berry AC, Berry RJ (1967) Epigenetic variation in the human cranium. J Anat 101:361–37.
22. Erdogmus S, Govsa F (2005) Importance of the anatomic features of the lacrimal artery for orbital approaches. J Craniofacl Surg 16: 957–964.
23. Liu S, Yan W, Wang G, Zhao R, Qiu H, Cao L, Wang H (2021) Topographic anatomy of the zygomatico-orbital artery: Implications for improving the safety of temporal augmentation. Plastic and Reconstructive Surgery 148:19–27.
24. Odobescu A, Williams HB, Gilardino MS (2012) Description of a communication between the facial and zygomaticotemporal nerves. J Plast Reconstr Aesthet Surg 65:1188–1192.
25. Totonchi A, Pashmini N, Guyuron B (2005) The zygomaticotemporal branch of the trigeminal nerve: An anatomical study. Plastic and reconstructive surgery 115:273–277.
26. Khalid S, Iwanaga J, Loukas M, Tubbs RS (2017) Bilateral absence of the zygomatic nerve and zygomaticofacial nerve and foramina. Cureus 9:7.
27. Zide MF, Wu J (1990) The placement of screws above the zygomaticofrontal suture. J Oral Maxillofac Surg 8:813–816.
28. Lone M, Telang A, Rajgopal L, Bhuiyan PS (2016) Location and incidence of the zygomatico-facial foramen in dry human skulls: an anatomical study. J Anat Soc India 65:164–166.
29. Mangalgiri AS, Satpathy DK, Bhojwani R (2015) Study of Os zygomaticum bipartitum in skulls of Central India. Journal of Indian Academy of Forensic Medicine 37:59–61.
30. Zhang Q, Zhang Q, Yang S, Dechow PC, Zhu H, Yeh HY, Wang Q (2019) Divided zygoma in Holocene human populations from Northern China. Am J Hum Biol 31:23314.
31. Anil A, Peker T, Turgut HB, Pelin C, Gülekon N (2000) Incidence of os japonicum in Anatolian dry skulls and plain cranium radiographs of modern Anatolian population. J Craniomaxillofac Surg 28:217–223.
32. Nikolova S, Toneva D, Georgiev I (2017) A case of bipartite zygomatic bone. European Journal of Forensic Sciences 4:1–4.

Figures

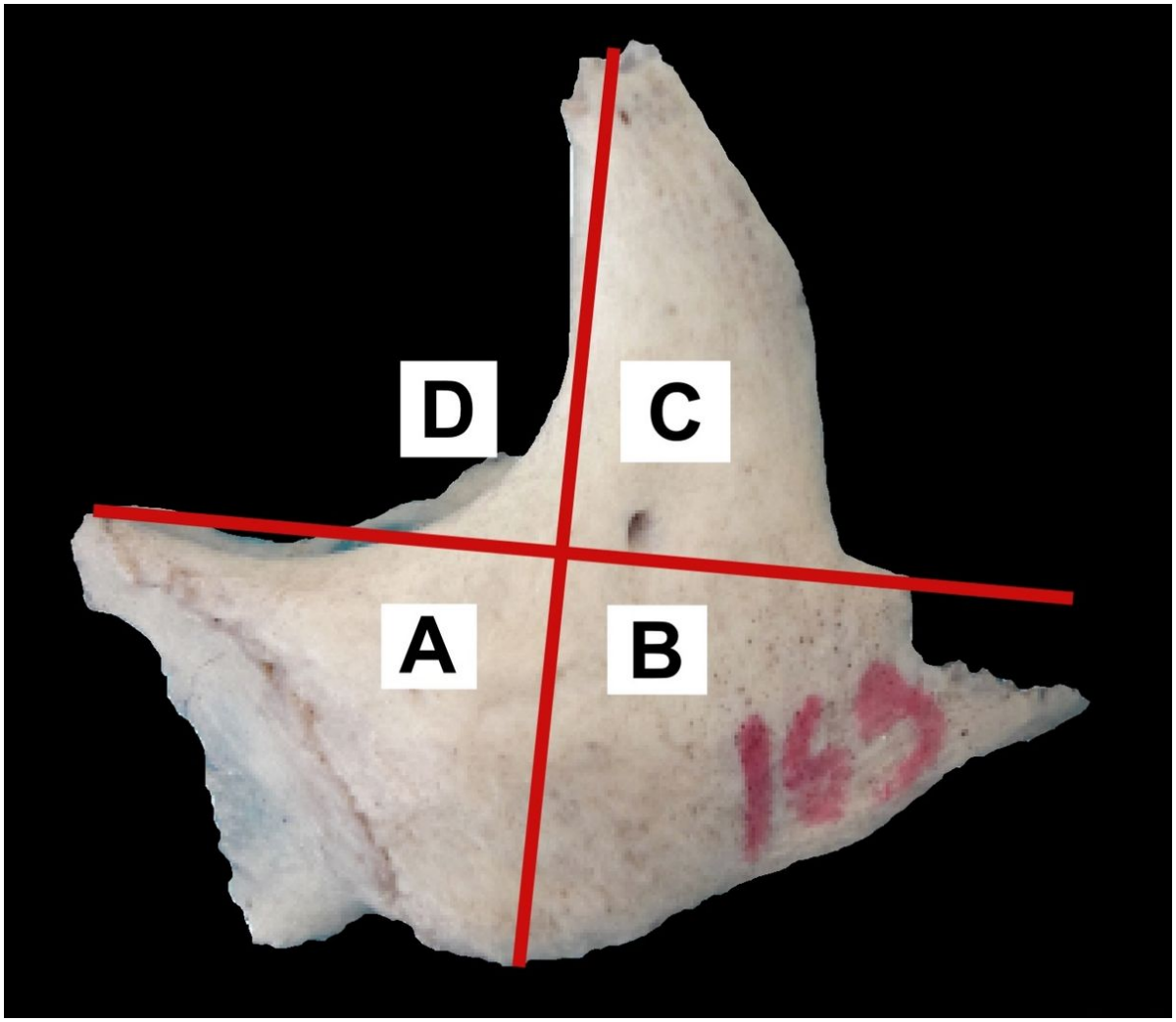

Figure 1

The Inferomedial (A), Inferolateral (B), Superolateral (C), and Superomedial (D) regions of zygomatic bone are indicated by the two red lines (vertical and transverse). The first (vertical) line is between the frontozygomatic suture and the lowest point of the zygomaticomaxillary suture, and the second (transverse) line is between the point where the angle formed by the frontal and temporal process and the inferior wall of the orbit medially.

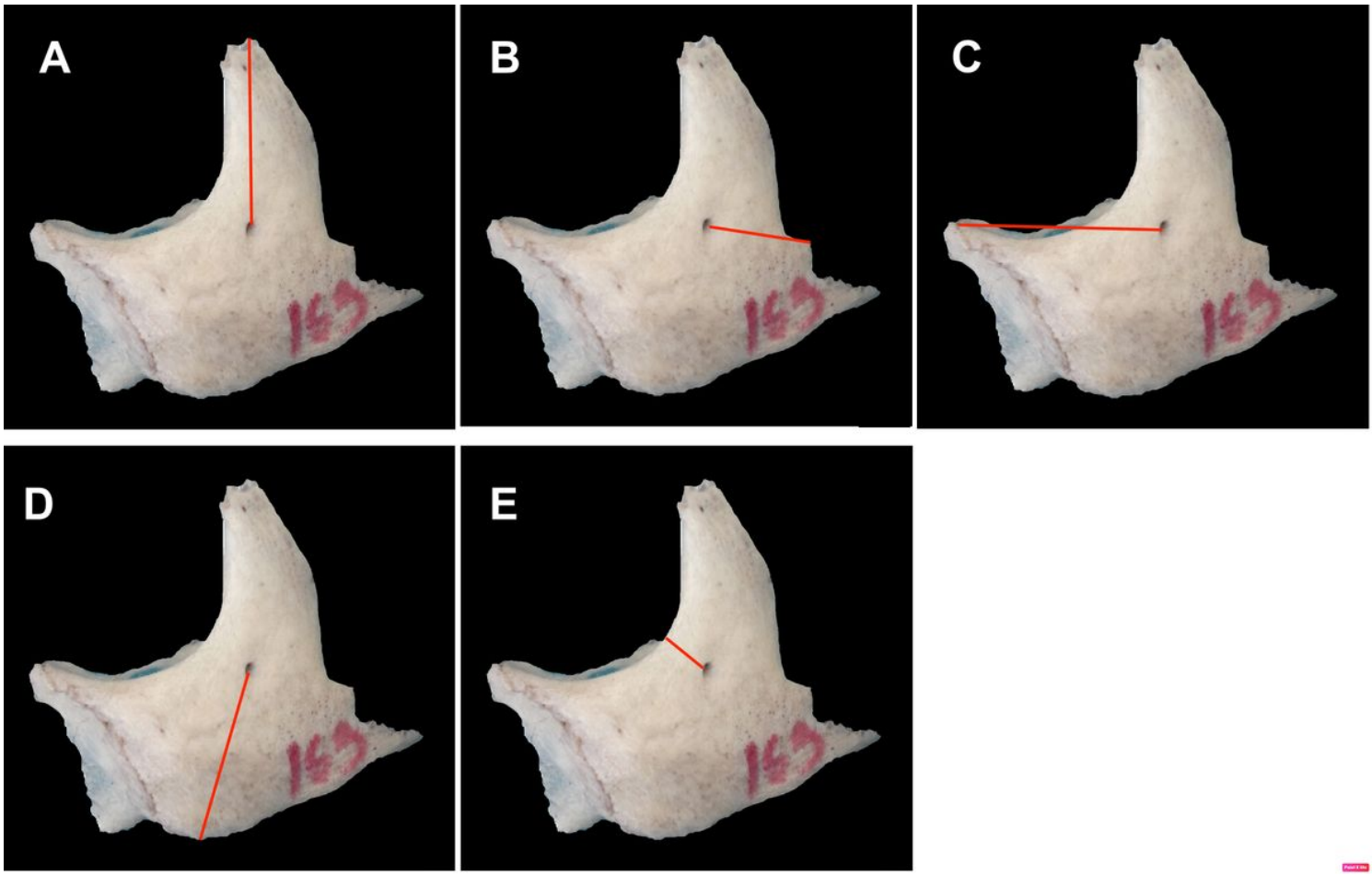

Figure 2

The distances (red lines) between the zygomaticofacial foramen and the anatomical landmarks. (A) the distance between the zygomaticofacial foramen and the frontozygomatic suture; (B), the distance between the zygomaticofacial foramen and zygomaticotemporal process; (C) the distance between the zygomaticofacial foramen and the maxillary process; (D), the distance between the zygomaticofacial foramen and the lowest point of the zygomaticomaxillary suture; (E), the distance between the zygomaticofacial foramen and the orbital rim.

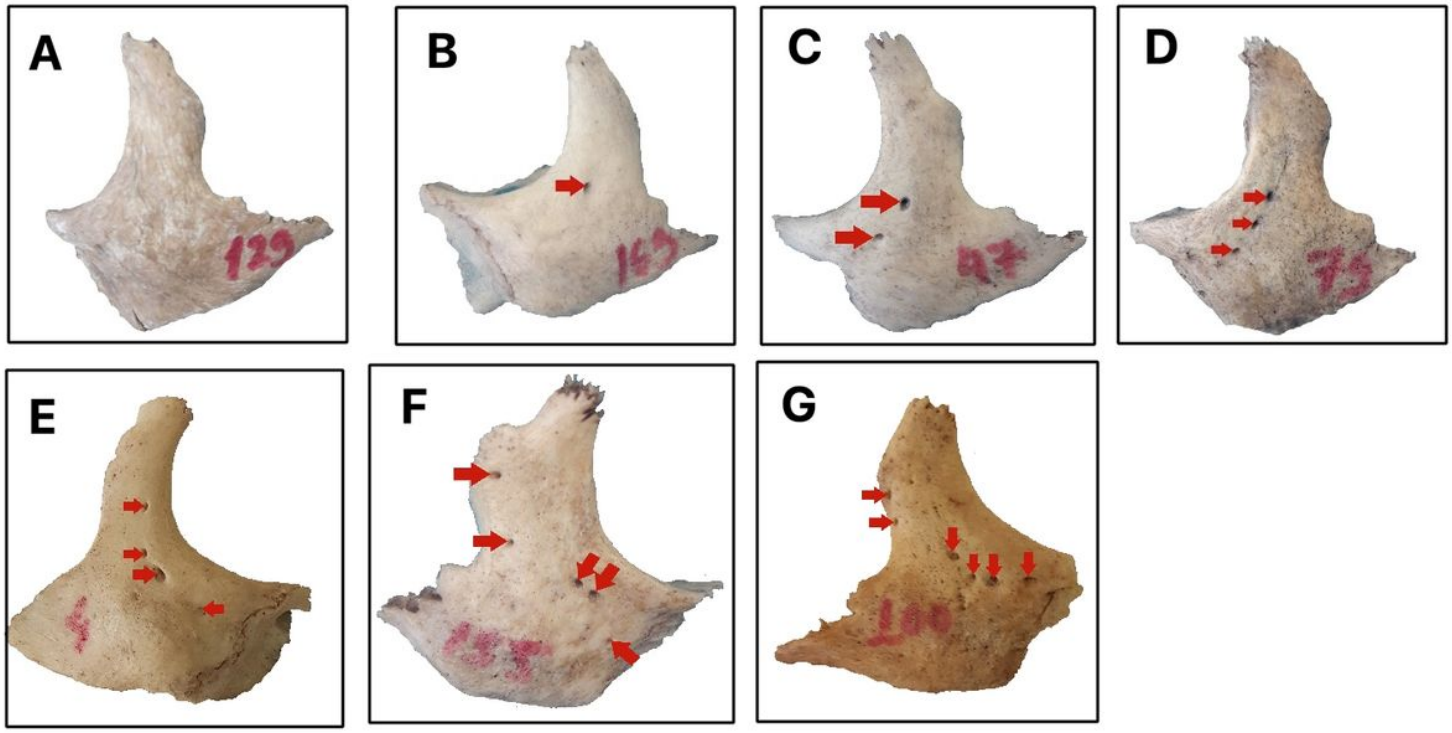

Figure 3

The number of zygomaticofacial foramina. (A) Absent foramen. (B) Single foramen. (C) Double foramina. (D) Three foramina. (E) Four foramina. (F) Five foramina. (G) Six foramina.