Article published online: 2021-01-04

A Fatal Case of COVID-19 in a Child with ALL: A Cytokine Storm and Hyperferritinemic MODS

Fulya Kamit[1] Baris Malbora[2] Avni Atay[2] Derya Turan Bayirli[3] Metin Bektas[4]

[1] Faculty of Medicine, Pediatric Intensive Care Unit, Istanbul Yeniyuzyil University, Istanbul, Turkey
[2] Faculty of Medicine, Pediatric Hematopoetic Stem Cell Transplant Unit, Istanbul Yeniyuzyil University, Istanbul, Turkey
[3] Faculty of Medicine, Department of Infectious Diseases and Clinical Microbiology, Istanbul Yeniyuzyil University, Istanbul, Turkey
[4] Faculty of Medicine, Department of Anesthesiology, Istanbul Yeniyuzyil University, Istanbul, Turkey

Address for correspondence Fulya Kamit, MD, Yeniyüzyıl Universitesi, Gaziosmanpaşa Hastanesi, Merkez, Çukurçeşme Cd. No:51, 34245 Gaziosmanpaşa/İstanbul, Turkey (e-mail: fulyakamit@yahoo.co.uk).

J Child Sci 2020;10:e240–e245.

Abstract

Since little is known about dysregulated hyperinflammatory immunological responses causing acute severe infection and multisystem inflammatory syndrome in children associated with coronavirus disease 2019 (COVID-19), the available data on therapies for severe presentations in children are very limited. Describing experiences of severe pediatric COVID-19 presentations in more detail will help improve clinical practice.

In this case report, we describe the complete clinical course of a 9-year-old girl previously diagnosed with Angelman syndrome and high-risk T cell acute lymphoblastic leukemia who had been receiving reinduction chemotherapy, presented with pneumonia and acute respiratory distress syndrome, and progressively developed hyperferritinemic multiple-organ failure, a cytokine storm, and coagulopathy associated with COVID-19. She was treated with therapeutic plasma exchange, tocilizumab, hydrocortisone, and favipiravir, but she died 7 days after her admission into our pediatric intensive care unit.

The utility of therapeutic plasma exchange with other immunomodulatory therapies in severe presentations requires further trials. The spectrum of the inflammatory phenotypes associated with COVID-19 should be investigated and well defined to initiate the optimal treatment strategy on time.

Keywords
- acute lymphoblastic leukemia
- coronavirus disease 2019 (COVID-19)
- critically ill children
- hyperferritinemia
- therapeutic plasma exchange

Introduction

As the worldwide outbreak of a new type of coronavirus spreads, coronavirus disease 2019 (COVID-19), new data has emerged, indicating an unignorable amount of severe presentations among the pediatric population.[1–7] Mortality has been reported among children developing progressive multiple-organ failure.[2–7]

Since little is known about dysregulated hyperinflammatory immunological responses causing the acute severe infection and multisystem inflammatory syndrome in children (MISC) associated with COVID-19, the available data on therapies for severe presentations in children are very limited.[3,4,6,7] Describing experiences of severe pediatric COVID-19 presentations in more detail will help improve clinical practice.

In this case report, we describe the complete clinical course of a 9-year-old girl diagnosed with high-risk T cell acute lymphoblastic leukemia (ALL) who had been receiving reinduction chemotherapy, presented with pneumonia and acute respiratory distress syndrome (ARDS), and progressively developed multiple-organ failure, a cytokine storm, and coagulopathy associated with COVID-19. She was treated with therapeutic plasma exchange (TPE), tocilizumab,

received
September 30, 2020
accepted after revision
November 5, 2020

DOI https://doi.org/10.1055/s-0040-1721513.
ISSN 2474-5871.

© 2020. The Author(s).
This is an open access article published by Thieme under the terms of the Creative Commons Attribution License, permitting unrestricted use, distribution, and reproduction so long as the original work is properly cited. (https://creativecommons.org/licenses/by/4.0/)

Georg Thieme Verlag KG, Rüdigerstraße 14, 70469 Stuttgart, Germany

hydrocortisone, and favipiravir, but she died 7 days after her admission into our pediatric intensive care unit (PICU).

Case

Our patient is a 9-year-old girl with mild motor–mental retardation due to Angelman syndrome who had also been diagnosed with high-risk T cell ALL 6 months previously, had been in remission after first-induction chemotherapy, and had been treated with high-risk blocks for the last 3 months. Eight days after the last time she was admitted to the ward to receive her high-risk block, she developed fever. She was administered antibiotics for febrile neutropenia, but she developed cough 4 days later. A chest X-ray was taken, and her initial diagnosis was fungal pneumonia. Empiric antibiotics were widened to vancomycin, meropenem, trimethoprim–sulfamethoxazole, amphotericin B, and ganciclovir. Her cough and fever persisted, and she was admitted to a PICU after she developed mild respiratory distress and oxygen requirement on the second day of her cough and the sixth day of her fever. She was provided noninvasive mechanical ventilation (NIV) with a full-face mask, continuous positive airway pressure 6 cm H_2O, fraction of inspired oxygen (F_iO_2) 40%. She had pneumonia with a SpO_2/F_iO_2 ratio of 277, normal blood gas analysis, and hemodynamical stability. After 16 hours on NIV, a chest X-ray and thorax computed tomography showed the progression of infiltrates (►**Fig. 1A–1I**) bilaterally, and she was electively intubated. The patient had mild pediatric ARDS with a P_aO_2/F_iO_2 ratio of 250. An endotracheal aspirate was taken for Gram staining, culture, influenzas A and B, and severe acute respiratory syndrome coronavirus 2 (SARS-CoV-2).

No bacteria was detected in Gram staining, and viral polymerase chain reaction (PCR) was negative for influenza. The patient was hemodynamically stable and received intravenous immunoglobulin, wide-spectrum antibiotics, and supportive care (blood products) without inotropes while waiting for the SARS-CoV-2 test result. Fifteen hours after intubation, she developed sinus tachycardia that was unresponsive to fluids and rapidly developed metabolic acidosis, renal failure, and hyperdynamic shock requiring noradrenalin and adrenaline infusion, and worsening oxygenation simultaneously. Continuous renal replacement therapy (CRRT) started immediately for metabolic acidosis, fluid expansion, inotrope, and fluids were titrated, and mean airway pressure and oxygen needed to be increased with a P_aO_2/F_iO_2 ratio of 56. The result of the PCR test for SARS-CoV-2 was then available, and the patient was diagnosed with COVİD-19 simultaneously. She progressively developed shock and multiple-organ failure in 5 hours, and tests showed high inflammatory markers, coagulopathy, and organ failure, consistent with the diagnosis for fulminant COVID-19. Favipiravir, hydrocortisone, tocilizumab, and vitamin C were added to supportive treatment. At the end of the day (on PICU day 3), her pupils were both mildly reactive to light and dilated. On PICU day 4, TPE was begun for severe sepsis with rapidly developing hyperferritinemic multiple-organ dysfunction syndrome (MODS) associated with a cytokine storm of fulminant COVID-19. A second dose of tocilizumab was given after TPE, and CRRT was continued with hydrocortisone, favipiravir, and other supportive care. Fresh frozen plasma was used as replacement fluid, and the patient received 1.5 plasma volume exchange on PICU day 4 and 5 followed by 1 volume exchange on PICU day 6 and 7. Laboratory findings,

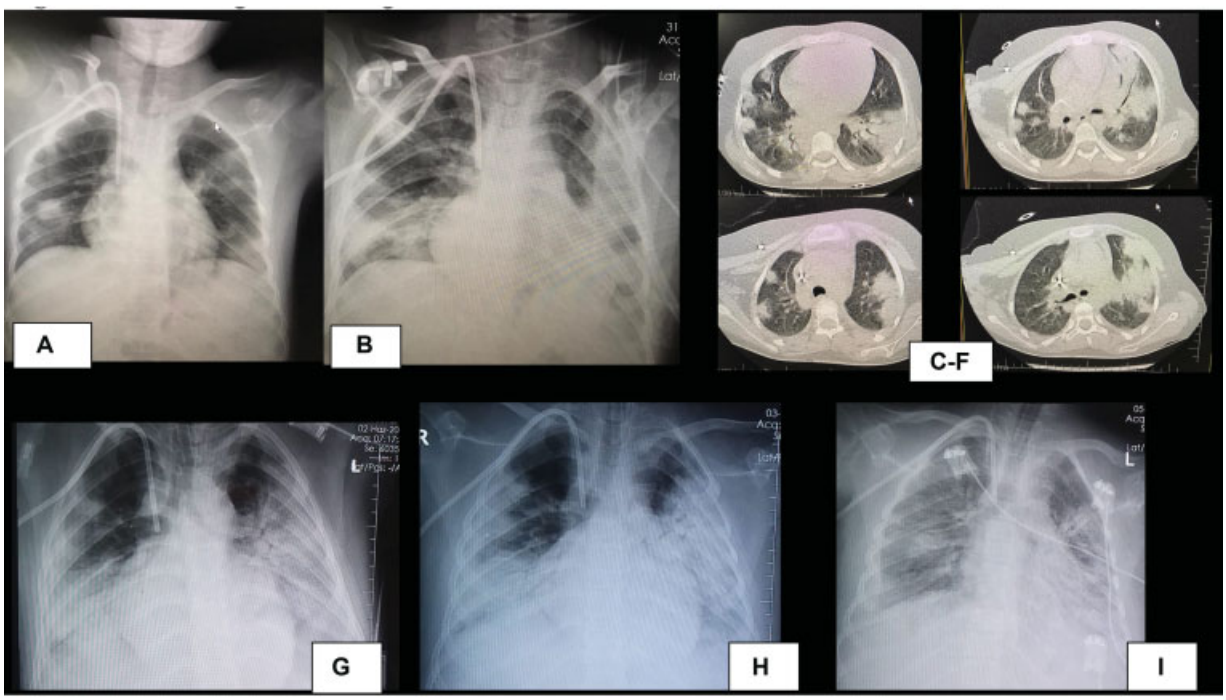

Fig. 1 (**A–B**) chest x-rays on PICU day 1–2, (**C–F**) thorax CT on PICU day 2, (**G–I**) chest x-rays on PICU day 3–4–7. Radiological findings.

Table 1 Laboratory findings, treatment, and notable clinical findings of the patient

	Onco. ward admission	PICU-day 1	PICU-day 2	PICU-day 3	PICU-day 4	PICU-day 5	PICU-day 6	PICU-day 7
WBC (mm^3)	2,120	40	30	510	5,040	16,570	15,280	25,590
Lymp/Neutro	760/780	–/–	–/–	140/300	490/4,160	1,600/13,480	700/12,690	600/22,190
Platelet	115000	8000	13,000	26,000	24,000	49,000	34,000	28,000
LDH (U/L)	140	212	259	1,864	2,578	1,147	1,156	1,005
Ferritin (ng/mL)				>100.000	>100.000	>100.000	80,879	45,268
PT/APTT (sec)	12.4/29.7		13.2/39.2	19.2/53	13.8/36.8 1.6	12.1/27.8	12.7/43.3	13.5/28.4
Fibrinogen(g/L)			4.5			1.42	1.31	1.27
TG (mg/dL)				278	255	481	504	410
AST/ALT(U/L)	42/62	110/16 7	115/153	862/252	1,825/662	1,794/760	303/232	144/91
BUN (mg/dL)	5.3	7.3	14.6	22.4	14	19.1	28.7	25.4
Crea. (mg/dL)	0.42	0.5	0.9	1.6	2.4	2.1	1.8	1.6
T.Bil(mg/dL)	0.43	0.83	0.49	0.89	1.77	1.32	1.9	1.5
D-dimer(mg/L)			8.74	19.44	8.55	>20	8.8	8.7
IL-6 (pg/mL)				25931		17140		
CRP (mg/L)	1.1	336.7	348.8	292.5	261.4	102.9	43.7	25.9
PCT (µg/L)			8.4	96.1	163.1	108		
Respiratory support	–	NIV, CPAP:6 S/F:277	iMV, PEEP:8, PIP:25 P/F:250	PEEP:14 PIP:35 P/F:56	PEEP:15 PIP:40 P/F:54, prone	PEEP:14 PIP:35 P/F:92, prone	PEEP:13 PIP:32 P/F:104, prone	PEEP:12 PIP:30 P/F:120, prone
Vasopressors (mcg/kg/min)		–	–	E(0.4)+ NE(0.8)	E(0.6) + NE(1)	E(0.4)+ NE(0.4)	E(0.2) + NE(0.3)	E(0.2)+ NE(0.2)
Lactate (mmol/L)		1.6–1.1	1–1.6	5.8–2.6	1.4–2.5	1.4–2.1	0.9–1.4	0.27
Clinical course	Stable	39°C NIV (4p.m)	39°C Elective intubation (10 AM) Hemodynamically stable	38.7°C, (03–06 AM): Sinus tachycardia, pH:6,9, Hypotension, EF:N Hypoglycemia renal failure SARS-CoV-2 PCR (+) Severe ARDS Weak pupillary	38.7°C MODS Weak pupillary reflexes, mid-dilated Sedation stopped Tracheal Asp. CMV PCR(-)	38°C MODS, EF:N, weak pupillary reflexes, mid-dilated Fundus: Retinal hemorrhage, papilloedema	38.2°C, Repeated cultures of tracheal aspirates, blood, urine: negative artışı Lower ext. USG: No thrombosis Profound acro-ischemia	37°C (11p.m): Fixed dilated pupillary, No gag reflex Exitus

Table 1 (*Continued*)

	Onco. ward admission	PICU-day 1	PICU-day 2	PICU-day 3	PICU-day 4	PICU-day 5	PICU-day 6	PICU-day 7
				reflexes, mid-dilated				
Treatment	2ndHR1 block: IT-IV Mtx, Vinc,CP, ARA-C,L-Asp, Dexa, IVIG	VMTAG, GCSF	VMTAG, GCSF, IVIG (40 gr) PLT/ES	CRRT, Favipiravir (1600mg) Tocilizumab (400mg) Hydrocortisone (200mg) VMTAG, GCSF, PLT/ES, Alb, CVIT (2 gr)	TPE(X1,5PV) CRRT Favipiravir(600mg) Tocilizumab (400mg) Hydrocortisone (200mg) VMTA, PLT/ES, CVIT (2 gr) LEVA, %3NaCl	TPE(X1,5PV) CRRT Favipiravir (600mg) Hydrocortisone (200mg), VMTA, PLT/ES, CVIT (2 gr), LEVA, %3NaCl	TPE(X1PV) CRRT Favipiravir(600mg) Hydrocortisone (200mg) VMTA PLT/ES, CVIT (2 gr) LEVA, %3NaCl	TPE(X1PV) CRRT Favipiravir (600mg) Hydrocortisone (200mg) VMTA PLT/ES, CVIT (2 gr) LEVA, %3NaCl

Abbreviations: Alb, albumin; ARA-C, cytosine arabinoside; BUN, blood urea nitrogen; CP, cyclophosphamide; CPAP, continuous positive airway pressure; Crea, creatinine; CRRT, continuous renal replacement therapy; CVIT, vitamin C; Dexa, dexamethasone; E, epinephrine; EF, ejection fraction; GCSF, granulocyte colony stimulated factor ; HR, high risk; IT-IV Mtx, intrathecal-intravenous methotrexate; IVIG, intravenous immunoglobulin; iMV, invasive mechanical ventilation; L-Asp, L-Asparaginase; LEVA, levetiracetam; MODS, multiple organ dysfunction syndrome; NE, norepinephrine; NIV, noninvasive mechanical ventilation; P/F, P_aO_2/F_iO_2 ratio; PCT, procalcitonin; PEEP, positive end-expiratory pressure; PICU, pediatric intensive care unit; PIP, peak inspiratory pressure; PLT/ES, thrombocyte/erythrocyte suspension; PV, plasma volume; S/F, SpO_2/F_iO_2 ratio; TG, triglyceride; TPE, therapeutic plasma exchange; USG, ultrasonography; Vinc, vincristine; VMTAG, vancomycin, meropenem, trimethoprim sulfomethoxazole, amphotericin B, ganciclovir.

treatment, and notable clinical findings for the patient are shown in ►**Table 1**.

With vasopressor support for shock, and conventional mechanical ventilation, X-ray findings showed improvement (►**Fig. 1A–1I**). Serum ferritin, C-reactive protein (CRP), lactate dehydrogenase (LDH), and interleukin-6 (IL-6) decreased, and the number of platelet suspensions decreased gradually after each TPE session. However, neurological findings remained unchanged, with mildly reactive pupillary reflexes to light, dilatation, and low Glasgow coma scale (E1M3V1) but preserved spontaneous breathing and gag reflex. Retinal hemorrhage and papilledema were detected on fundus examination. Sedation was stopped, levetiracetam was given for potential seizures, and antiedema treatment was given for probable increased intracranial pressure. On PICU day 6, acro-ischemia occurred (►**Fig. 2**), but a lower-extremity ultrasound did not show thrombosis. Repeated cultures of endotracheal aspiration and other sides for bacteria and fungus were negative. She died on PICU day 7 because of severe neurological dysfunction.

Discussion

Turkey's first COVID-19 cases were confirmed on March 11, 2020. By September 1, 2020, COVID-19 had caused 6,326 deaths in the country, including 12 people under 15 years of age.[8]

Severe presentations associated with COVID-19 in children are defined as *MISC*, a postinfectious inflammatory process that has mostly affected children who had previously been healthy. Severe COVID-19 disease is an acute severe infection reported in children and the adult population with existing comorbidities.[7,9] Also recently, subgroups of MISC have been defined with different manifestations but a similar process.[7] The primary hallmark is a hyperinflammatory state because of a dysregulated immune response triggered by the novel coronavirus, resulting in MODS and coagulopathy, which have been found to predict severity.[1,6,9–11] Our patient had profound immunosuppression with very low lymphocyte and neutrophil counts ($10/mm^3$) from the beginning of treatment due to high-risk chemotherapy. She developed severe ARDS and MODS progressively after COVID-19 pneumonia and, finally, acro-ischemia attributed to microthrombosis. She experienced a cytokine storm and COVID-19 coagulopathy that mimicked adult fulminant COVID-19 cases and presented with predictors of a fatal outcome, such as very high ferritin, CRP, D-dimer, and IL-6.[10–13]

The patient had several clinical features of secondary hemophagocytic lymphohistiocytosis (HLH), macrophage activation syndrome (MAS), and thrombocytopenia-associated multiple-organ failure (TAMOF)—that is, phenotypes of hyperferritinemic, critically ill diseases with MODS, such as highly elevated ferritin, elevated transaminases, elevated LDH, thrombocytopenia, and lymphopenia. These symptoms have also been reported in acute severe COVID-19, and MISC patients.[9,10,14,15] COVID-19–induced cytokine storm with the characteristic coagulopathy of COVID-19 has common pathogenesis and clinical as well as laboratory findings with severe sepsis and MODS, secondary HLH, MAS, and TAMOF.[15–17] Hyperferritinemic MODS in severe



Fig. 2 Profound acro-ischemia images.

sepsis, due to either COVID-19 or other agents, has been strongly associated with a poor prognosis.[9,10,18]

Our patient had profound thrombocytopenia with high fibrinogen and markedly elevated D-dimer levels. Her D-dimer levels remained elevated, with lower levels of fibrinogen and normal ranges for prothrombin time and activated partial thromboplastin time. Laboratory findings and the patient's clinical course showed overlapping coagulopathies, such as a spectrum of TAMOF (thrombotic thrombocytopenic purpura, thrombotic microangiopathy, and sepsis-induced disseminated intravascular coagulation [DIC]), but she also had unique features of COVID coagulopathy, such as very high D-dimer levels, low-grade DIC, and microthrombosis.[16,19]

Therapeutic strategies targeting this overactive cytokine response for severe COVID-19 patients are available, but they have not yet been approved.[20] TPE has been shown to remove the proinflammatory cytokines leading to MODS and, furthermore, restore hemostasis and resolve organ dysfunction in patients with hyperferritinemic syndromes, such as severe sepsis and MODS, secondary HLH, MAS, and TAMOF phenotypes.[21–23] Observational studies have examined TPE's utility in the clinical course of these types of critical diseases.[24–27] Moreover, a recent case and case series have reported improved outcomes for severe COVID-19 patients sharing many features with the critical diseases treated using TPE.[14,28,29]

Our patient was treated with tocilizumab, favipiravir, and hydrocortisone, combined with TPE. Hemodynamics, organ dysfunction (pulmonary, hepatic, hematologic, and cardiovascular), and inflammatory markers had shown improvements after TPE sessions, beginning from the first TPE session, but severe neurological dysfunction had not improved. Unfortunately, the patient died of central nervous system complications that may have been due to inflammation or infection (brain edema) or coagulopathy (hemorrhage or infarction). Furthermore, we think that the multidrug therapy patient received did not have a negative effect on the brain. Our fateful limitation was that we could not diagnose these complications because of transport issues to the radiology department.

Our patient's mother and the healthcare workers tested negative for SARS-CoV-2. The management of COVID-19 pneumonia in profoundly immunocompromised patients is far different from other etiologies. Two precious days before intubation might have been the critical point for testing that we missed in this case. Following this case, our institution has implemented a practice of administering SARS-CoV-2 PCR tests for all immunocompromised patients with pneumonia and/or fever, regardless of their history of contact.

The inflammatory phenotypes and courses of organ dysfunction of severe presentations are not homogenous, but some subgroups of MISC and acute fulminant COVID-19 have similar features. These similar features are rapidly progressive and fatal with MODS and hyperinflammation with abnormal coagulopathy.[9] Although there is insufficient evidence to support TPE with other immunomodulatory treatments, such as anakinra or tocilizumab, we think they should begin early in the course, especially before the initiation of invasive mechanical ventilation in the severe group. Close monitoring of laboratory findings—such as LDH, ferritin, CRP, D-dimer, and IL-6, if possible, and H Score along with organ dysfunction and oxygen requirement—is important for not missing the critical point of treatment.[30]

The utility of TPE with other immunomodulatory therapies in severe presentations requires further trials. The spectrum of the inflammatory phenotypes associated with COVID-19 should be investigated and well defined to initiate the optimal treatment strategy on time. According to the relevance of overlap, we think TPE might be beneficial individually or in combination with other immunomodulatory treatments for a subgroup of severe (both acute infection and MISC) COVID-19 patients, like experience in secondary HLH and TAMOF.[21,22,24]

Conflict of Interest
None declared.

References

1 Wang Y, Zhu F, Wang C, et al. Children hospitalized with severe COVID-19 in Wuhan. Pediatr Infect Dis J 2020;39(07):e91–e94
2 Zachariah P, Johnson CL, Halabi KC, et al; Columbia Pediatric COVID-19 Management Group. Epidemiology, clinical features, and disease severity in patients with coronavirus disease 2019 (COVID-19) in a Children's Hospital in New York City, New York. [published online ahead of print, 2020 Jun 3] JAMA Pediatr 2020; 174(10):e202430
3 Shekerdemian LS, Mahmood NR, Wolfe KK, et al; International COVID-19 PICU Collaborative. Characteristics and outcomes of children with coronavirus disease 2019 (COVID-19) infection

admitted to US and Canadian Pediatric Intensive Care Units. [published online ahead of print, 2020 May 11]JAMA Pediatr 2020;174(09):868–873
4 DeBiasi RL, Song X, Delaney M, et al. Severe coronavirus disease-2019 in children and young adults in the Washington, DC, metropolitan region. J Pediatr 2020;223:199–203.e1
5 Chao JY, Derespina KR, Herold BC, et al. Clinical characteristics and outcomes of hospitalized and critically ill children and adolescents with coronavirus disease 2019 at a Tertiary Care Medical Center in New York City. J Pediatr 2020;223:14–19.e2
6 Hoang A, Chorath K, Moreira A, et al. COVID-19 in 7780 pediatric patients: a systematic review. EClinicalMedicine 2020; 24:100433. Doi: 10.1016/j.eclinm.2020.100433
7 Godfred-Cato S, Bryant B, Leung J, et al;California MIS-C Response Team. COVID-19-associated multisystem inflammatory syndrome in children - United States, March-July 2020. MMWR Morb Mortal Wkly Rep 2020;69(32):1074–1080
8 REPUBLİC OF TURKEY MINISTRY OF HEALTH COVID-19 Situation Report. Available at: https://sbsgm.saglik.gov.tr/TR,68773/covid-19-situation-report-turkey-eng.html. Accessed September 2, 2020
9 Diorio C, Henrickson SE, Vella LA, et al. Multisystem inflammatory syndrome in children and COVID-19 are distinct presentations of SARS-CoV-2. [published online ahead of print]J Clin Invest 2020; 130(11):5967–5975
10 Ruan Q, Yang K, Wang W, Jiang L, Song J. Clinical predictors of mortality due to COVID-19 based on an analysis of data of 150 patients from Wuhan, China. [published correction appears in Intensive Care Med. 2020 Apr 6;]Intensive Care Med 2020;46(05): 846–848
11 Wu C, Chen X, Cai Y, et al. Risk factors associated with acute respiratory distress syndrome and death in patients with coronavirus disease 2019 pneumonia in Wuhan, China. JAMA Intern Med 2020;180(07):934–943
12 Bonetti G, Manelli F, Patroni A, et al. Laboratory predictors of death from coronavirus disease 2019 (COVID-19) in the area of Valcamonica, Italy. Clin Chem Lab Med 2020;58(07): 1100–1105
13 Levi M, Thachil J, Iba T, Levy JH. Coagulation abnormalities and thrombosis in patients with COVID-19. Lancet Haematol 2020;7 (06):e438–e440
14 Latimer G, Corriveau C, DeBiasi RL, et al. Cardiac dysfunction and thrombocytopenia-associated multiple organ failure inflammation phenotype in a severe paediatric case of COVID-19. Lancet Child Adolesc Health 2020;4(07):552–554
15 Mehta P, McAuley DF, Brown M, Sanchez E, Tattersall RS, Manson JJHLH Across Speciality Collaboration, UK. COVID-19: consider cytokine storm syndromes and immunosuppression. Lancet 2020;395(10229):1033–1034
16 Iba T, Levy JH, Connors JM, Warkentin TE, Thachil J, Levi M. The unique characteristics of COVID-19 coagulopathy. Crit Care 2020; 24(01):360. Doi: 10.1186/s13054-020-03077-0
17 Liu B, Li M, Zhou Z, Guan X, Xiang Y. Can we use interleukin-6 (IL-6) blockade for coronavirus disease 2019 (COVID-19)-induced cytokine release syndrome (CRS)? J Autoimmun 2020; 111:102452. Doi: 10.1016/j.jaut.2020.102452
18 Bennett TD, Hayward KN, Farris RW, Ringold S, Wallace CA, Brogan TV. Very high serum ferritin levels are associated with increased mortality and critical care in pediatric patients. Pediatr Crit Care Med 2011;12(06):e233–e236
19 Nguyen TC, Carcillo JA. Bench-to-bedside review: thrombocytopenia-associated multiple organ failure–a newly appreciated syndrome in the critically ill. Crit Care 2006;10(06):235. Doi: 10.1186/cc5064
20 COVID-19 Treatment Guidelines Panel Coronavirus Disease. 2019 (COVID-19) Treatment Guidelines. National Institutes of Health . Available at: https://www.covid19treatmentguidelines.nih.gov/. Accessed September 2, 2020
21 Demirkol D, Yildizdas D, Bayrakci B, et al;Turkish Secondary HLH/MAS Critical Care Study Group. Hyperferritinemia in the critically ill child with secondary hemophagocytic lymphohistiocytosis/sepsis/multiple organ dysfunction syndrome/macrophage activation syndrome: what is the treatment? Crit Care 2012;16(02): R52
22 Demirkol D, Carcillo J. Management of the critically ill child with the sepsis/hemophagocytic lymphohistiocytosis/macrophage activation syndrome overlap syndrome. J Pediatr Intensive Care 2014;3(04):243–254
23 Rosário C, Zandman-Goddard G, Meyron-Holtz EG, D'Cruz DP, Shoenfeld Y. The hyperferritinemic syndrome: macrophage activation syndrome, Still's disease, septic shock and catastrophic antiphospholipid syndrome. BMC Med 2013;11:185
24 Fortenberry JD, Nguyen T, Grunwell JR, et al;Thrombocytopenia-Associated Multiple Organ Failure (TAMOF) Network Study Group. Therapeutic plasma exchange in children with thrombocytopenia-associated multiple organ failure: the thrombocytopenia-associated multiple organ failure network prospective experience. Crit Care Med 2019;47(03):e173–e181
25 Sevketoglu E, Yildizdas D, Horoz OO, et al. Use of therapeutic plasma exchange in children with thrombocytopenia-associated multiple organ failure in the Turkish thrombocytopenia-associated multiple organ failure network. Pediatr Crit Care Med 2014; 15(08):e354–e359
26 Patel P, Nandwani V, Vanchiere J, Conrad SA, Scott LK. Use of therapeutic plasma exchange as a rescue therapy in 2009 pH1N1 influenza A–an associated respiratory failure and hemodynamic shock. Pediatr Crit Care Med 2011;12(02):e87–e89
27 Keith PD, Wells AH, Hodges J, Fast SH, Adams A, Scott LK. The therapeutic efficacy of adjunct therapeutic plasma exchange for septic shock with multiple organ failure: a single-center experience. Crit Care 2020;24(01):518
28 Morath C, Weigand MA, Zeier M, Speer C, Tiwari-Heckler S, Merle U. Plasma exchange in critically ill COVID-19 patients. Crit Care 2020;24(01):481
29 Gucyetmez B, Atalan HK, Sertdemir I, Cakir U, Telci LCOVID-19 Study Group. Therapeutic plasma exchange in patients with COVID-19 pneumonia in intensive care unit: a retrospective study. Crit Care 2020;24(01):492
30 Fardet L, Galicier L, Lambotte O, et al. Development and validation of the HScore, a score for the diagnosis of reactive hemophagocytic syndrome. Arthritis Rheumatol 2014;66(09):2613–2620