Journal of Integrated
SCIENCE & TECHNOLOGY

Oxidative stress, Sperm DNA fragmentation, and Varicocele: From mechanisms to precision management in male infertility

Sulagna Dutta[1,2]*, Pallav Sengupta[3]*, Tulay Irez[4], Emre Salabas[5]

[1]Basic Medical Sciences Department, College of Medicine, Ajman University, Ajman, UAE. [2]Centre of Medical and Bio-allied Health Sciences Research, Ajman University, Ajman, UAE [3]Department of Biomedical Sciences, College of Medicine, Gulf Medical University, Ajman, UAE [4]Department of Histology & Embryology, Istanbul Yeni Yuzyil University, Istanbul, Turkey [5]Department of Urology, Faculty of Medicine, Biruni University, Istanbul, Turkey

Submitted on: 12-Feb-2026, Revised: 10-May-2026, Accepted and Published on: 18-May-2026

Review

ABSTRACT

Varicocele remains the most prevalent correctable finding in male infertility, yet its clinical interpretation is increasingly challenged by the limited explanatory power of conventional semen analysis. Emerging evidence positions varicocele as a biologically active lesion characterized by redox imbalance and downstream genomic instability, rather than a purely anatomical venous disorder. Oxidative stress (OS) and sperm DNA fragmentation (SDF) have therefore gained translational relevance as mechanistic intermediates linking varicocele to impaired fertilization, defective embryogenesis, recurrent pregnancy loss, and suboptimal assisted reproductive outcomes. Mechanistically, varicocele induces a convergence of hyperthermia, venous stasis, hypoxia-like stress, inflammation, and mitochondrial dysfunction, culminating in excessive reactive oxygen species (ROS) generation and failure of redox homeostasis. Given the intrinsic vulnerability of spermatozoa, characterized by limited antioxidant defenses and minimal DNA repair capacity, this oxidative milieu promotes lipid peroxidation, chromatin destabilization, and DNA strand breaks. Clinical syntheses consistently demonstrate elevated SDF in men with varicocele and indicate that varicocelectomy can reduce oxidative damage markers and SDF in selected patients, supporting a biologically responsive axis rather than incidental association. Despite these advances, critical uncertainties persist regarding assay standardization, clinically actionable SDF thresholds, and the extent to which biomarker improvement translates into live birth benefit. Current guidelines recommend selectively using SDF in clinical decisions for unexplained infertility, recurrent pregnancy loss, and ART failure, shifting toward phenotype-driven care. The OS-SDF-varicocele axis moves male infertility from descriptive approaches to mechanism-based precision treatment. Progress relies on molecular phenotyping, validating outcome-linked biomarkers, and redefining 'idiopathic' infertility into biologically distinct groups.

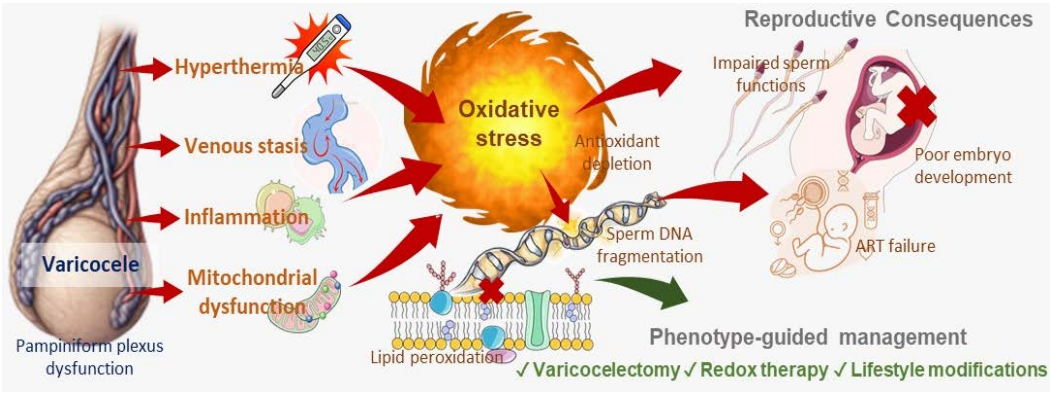

Keywords: Varicocele; Oxidative stress; Sperm DNA fragmentation; Male infertility; Precision andrology

INTRODUCTION

Varicocele remains the most common correctable clinical finding in men presenting with infertility, yet its biological significance is still too often underestimated when evaluation is restricted to conventional semen analysis alone. Recent guidance on male infertility increasingly recognises that concentration, motility, and morphology do not comprehensively address the functional and molecular deficiencies affecting reproductive competence, especially among men whose clinical presentations are inconsistent with conventional semen analysis results.[1, 2] Within this gap, oxidative stress (OS) and sperm DNA fragmentation (SDF) have emerged as highly relevant translational constructs, because they provide a mechanistic bridge between a palpable

*Corresponding Author: Sulagna Dutta, PhD., Basic Medical Sciences Department, College of Medicine, Ajman University, Ajman, UAE. Email: sulagna_dutta11@yahoo.com Pallav Sengupta, PhD., Department of Biomedical Sciences, College of Medicine, Gulf Medical University, Ajman, UAE. E-mail: pallav_cu@yahoo.com

Cite as: *J. Integr. Sci. Technol., 2026, 14(6), 1593.*
URN:SCN:jist.2026.v14.1593
DOI:10.62110/sciencein.jist.2026.v14.1593

©Authors CC4-NC-ND, ScienceIN https://pubs.thesciencein.org/jist

venous abnormality and impaired fertilization, defective embryo development, recurrent pregnancy loss, and suboptimal assisted-reproduction outcomes.[3,4]

Varicocele involves more than dilated pampiniform veins as it disrupts testicular homeostasis, leading to hyperthermia, venous stasis, hypoxia, poor microcirculation, inflammation, and mitochondrial dysfunction, all of which increase reactive oxygen species (ROS) production. Because spermatozoa possess lipid-rich membranes, limited cytoplasmic antioxidant reserves, and minimal post-meiotic DNA repair capacity, they are particularly vulnerable to oxidative injury. The consequence is not merely membrane lipid peroxidation or impaired motility, but a broader collapse of sperm functional integrity that includes oxidative base damage, chromatin destabilization, and DNA strand breaks.[5-7]

This framework has important clinical implications. Recent systematic reviews and meta-analyses support the association of clinical varicocele with elevated SDF and further indicate that varicocele repair can reduce SDF and seminal oxidative-damage markers in selected infertile men, although assay heterogeneity and patient selection remain important limitations.[8, 9] Following this, the field is shifting from an anatomic description of varicocele toward a precision model in which oxidative burden and sperm genomic injury help identify the men most likely to benefit from targeted intervention. This review therefore examines the OS-SDF-varicocele axis from mechanism to management, with particular emphasis on biologically informed diagnosis and precision therapeutic decision-making.

VARICOCELE AS A BIOLOGICAL DISEASE, NOT MERELY A VENOUS LESION

Definition, epidemiology, and clinical grading

Varicocele is generally described as the abnormal dilatation and tortuous enlargement of the pampiniform plexus, resulting from retrograde blood flow within the internal spermatic veins. However, this anatomical characterization only captures the superficial aspect of the condition and does not fully encompass the underlying biological complexities that contribute to its clinical significance. In reproductive medicine, varicocele matters because it is one of the commonest identifiable and potentially correctable findings in infertile men, yet its clinical meaning is unevenly distributed across patients. Population-based and infertility-focused reviews consistently place its prevalence at roughly 15% in the general male population, rising to about one-third of men with primary infertility and substantially higher in secondary infertility cohorts, although the exact proportion varies with recruitment strategy, age, examination method, and whether subclinical lesions are counted.[10,11] The lesion is predominantly left-sided because the left gonadal vein drains into the left renal vein at a less favourable angle and under higher hydrostatic conditions than the right, while bilateral disease is not rare and isolated right-sided varicocele remains uncommon enough to justify careful clinical scrutiny.[11,12]

Clinical grading continues to employ the Dubin-Amelar framework due to its ongoing practical utility in clinical settings: grade I lesions are palpable solely during a Valsalva manoeuvre, grade II are palpable without Valsalva, and grade III are visible through the scrotal skin; subclinical varicocele is detectable exclusively by imaging techniques.[11,13] However, current understanding in the field recognises that clinical grade does not necessarily reflect the biological severity of the condition. A visible grade III varicocele is not automatically a biologically aggressive lesion, and a smaller palpable lesion may still coexist with marked sperm dysfunction, elevated oxidative burden, or SDF. This is precisely why modern guidance does not recommend treatment based on ultrasound detection alone, but rather within an infertile couple context after integrating physical findings, semen quality, and increasingly, selected functional biomarkers.[1, 2] Thus, epidemiology and grading remain important descriptors, but they are insufficient surrogates for pathogenic activity. In contemporary andrology, varicocele should be viewed not simply as a venous abnormality, but as a clinically heterogeneous disorder whose reproductive significance depends on the biology it generates rather than the size it displays.

Pathophysiological basis of testicular dysfunction in varicocele

Varicocele disrupts local testicular homeostasis, starting with venous reflux and stasis. This leads to cellular metabolic, endocrine, and redox imbalances. The dilated pampiniform plexus fails to regulate temperature efficiently, causing chronic heat stress to the testis. At the same time, increased venous pressure, sluggish outflow, and disturbed microcirculation promote relative hypoxia and reperfusion-like oxidative injury. Additional mechanisms proposed in recent reviews include reflux of renal or adrenal metabolites, blood-testis barrier perturbation, endothelial dysfunction, inflammatory activation, and mitochondrial impairment within germ cells and supporting somatic cells.[6,14,15]

What emerges from this mechanistic literature is not a single dominant pathway, but a systems-level insult centered on OS. Testicular tissue exposed to hyperthermia, hypoxia, and inflammation tends to generate excessive ROS, while spermatozoa themselves remain intrinsically vulnerable because their membranes are rich in polyunsaturated fatty acids and their post-meiotic DNA repair capacity is limited. Under these conditions, oxidative injury extends beyond reduced motility or membrane peroxidation: it can compromise Sertoli-cell support, alter Leydig-cell steroidogenic function, destabilize chromatin packaging, impair mitochondrial bioenergetics, and increase SDF.[6,16,17] This broader framework explains why varicocele-associated infertility cannot be reduced to a mere ‘temperature effect’ or to simple venous dilatation. It is a disorder of biological amplification in which a structural lesion perturbs multiple interdependent testicular processes until spermatogenesis, sperm maturation, and genomic integrity begin to fail. The clinically relevant question, therefore, is not whether varicocele is present, but whether it has crossed the threshold at which vascular abnormality becomes molecular disease.

Why only some men with varicocele become infertile?

One of the central paradoxes in varicocele research is that many affected men remain fertile. Reviews continue to note that a substantial proportion of men with varicocele retain normal fecundity, which immediately argues against any deterministic model in which venous dilatation alone explains infertility.[6,11] This inconsistency is not a weakness of the varicocele hypothesis; it is evidence that the disorder is biologically stratified. Some men

appear to harbor a compensated state in which antioxidant defenses, mitochondrial resilience, effective spermatogenic reserve, and perhaps more favorable venous anatomy together buffer the lesion's downstream effects. Others progress to a decompensated phenotype marked by oxidative overload, inflammatory activation, defective chromatin packaging, impaired semen quality, and elevated SDF. In that sense, varicocele is less a binary diagnosis than a susceptibility-dependent stress test imposed on the testis.

Several modifiers probably determine where an individual patient lies on this compensated-to-decompensated spectrum. Clinical grade and disease duration matter, but they are not sufficient. Current literature points instead to a multivariable interaction involving baseline spermatogenic reserve, bilateral involvement, intensity of OS, inflammatory tone, environmental and metabolic co-exposures, and individual molecular susceptibility, including pathways identifiable through emerging proteomic and metabolomic work.[16,18,19] This helps explain why conventional semen analysis alone often underperforms: two men with apparently similar varicocele grades may carry very different burdens of subcellular injury. It also explains why modern guidelines increasingly frame management around infertile couple context and selected adjunctive biomarkers rather than anatomy alone.[1,2] The practical implication is decisive. Fertility impairment in varicocele is not universal because the lesion is filtered through host biology. Precision management therefore requires identification of the men in whom compensatory mechanisms have failed-those in whom varicocele has become a redox-inflammatory-genomic disorder rather than a merely dilated vein.

OXIDATIVE STRESS IN VARICOCELE

Redox physiology in sperm

A rigorous examination of OS in varicocele should commence with a clarification: ROS are not inherently detrimental within sperm biology. Spermatozoa rely on carefully regulated redox signaling to achieve and perform fertilizing capabilities. Low, spatially restricted ROS flux contributes to capacitation-associated protein phosphorylation, membrane remodeling, hyperactivation, and the acrosome reaction; in that sense, ROS participates in the biochemical conversion of a structurally mature spermatozoon into a functionally competent gamete.[20-22] This important role of ROS shows that simply assuming 'less ROS is always better' is no longer a valid perspective. Redox regulation in sperm operates within a narrow functional window: below that range, signaling required for fertilization becomes inefficient; above it, oxidative injury rapidly predominates.[23-25]

Varicocele becomes relevant precisely because it pushes this redox system away from physiological signaling toward oxidative overload. The transition is not only quantitative but qualitative. In the normal state, ROS-mediated signaling is brief, compartmentalized, and counterbalanced by seminal and intracellular antioxidant defenses. In varicocele, persistent thermal stress, venous stasis, mitochondrial dysfunction, and inflammatory activation convert controlled redox signaling into sustained oxidative pressure, so that the same molecular species that support capacitation begin to damage lipids, proteins, and nucleic acids.[6,26] Thus, OS in varicocele should not be framed as the mere presence of ROS, but as a failure of redox governance.

This conceptual distinction has direct clinical relevance, as it explains why indiscriminate antioxidant use may be biologically inappropriate, why reductive stress warrants consideration, and why biomarker interpretation should remain phenotype-specific rather than absolute. In varicocele-associated infertility, the key issue is not whether ROS exists in semen, it always does, but whether redox signaling has crossed the threshold beyond which physiological function gives way to molecular damage, defective fertilization, and genomic instability.[24,27]

Why sperm are highly vulnerable to oxidative injury?

Spermatozoa are unusually susceptible to oxidative damage because they combine intense metabolic specialization with structural simplicity. Their plasma membrane is enriched in polyunsaturated fatty acids, which confer the fluidity required for membrane fusion events but also create an ideal substrate for lipid peroxidation. Once peroxidation is initiated, membrane architecture destabilizes, ion gradients deteriorate, and the mechanical basis of motility begins to fail. This is not a trivial biochemical side effect but it is a direct assault on fertilizing competence.[23,26]

Their second vulnerability lies in the peculiar biology of sperm chromatin. During spermiogenesis, most histones are replaced by protamines, producing dense nuclear packaging that protects the paternal genome but also leaves little opportunity for later repair if damage occurs. Mature spermatozoa are transcriptionally silent, cytoplasm-deficit, and largely devoid of the enzymatic machinery required for effective DNA repair. Consequently, oxidative lesions that would be corrected in somatic cells may persist in sperm as strand breaks, oxidative base modifications, and chromatin destabilization.[27,28] The same biological strategy that allows sperm to function as streamlined delivery vehicles also leaves them extraordinarily exposed once redox balance is lost.

A third point is mitochondrial exposure. Sperm movement depends on tightly regulated mitochondrial functions, particularly in the midpiece, yet mitochondria are both generators and targets of ROS. When OS rises, mitochondrial membrane potential declines, ATP production becomes inefficient, and electron leakage further amplifies ROS generation, creating a self-reinforcing cycle of bioenergetic failure and oxidative injury.[16,26] In varicocele, this vulnerability is intensified by hyperthermia, hypoxia-like stress, and inflammatory signaling, all of which increase the likelihood that mitochondrial dysfunction and DNA injury will develop in parallel.[6,16] Therefore, oxidative damage to sperm associated with varicocele constitutes a systemic dysfunction that compromises motility, chromatin integrity, and fertilization capacity, rather than merely impacting membranes or DNA.

Sources of oxidative stress in varicocele

The oxidative burden associated with varicocele is mechanistically plural. Hyperthermia remains one of the best-established drivers. The pampiniform plexus normally supports countercurrent heat exchange, but venous dilatation and reflux compromise that function, exposing the testis to chronic temperature elevation. Heat stress perturbs mitochondrial respiration, promotes protein misfolding, and increases ROS

generation within germ cells and spermatozoa. Yet hyperthermia alone does not explain the full phenotype. Current evidence supports a composite model in which venous hypertension, altered microcirculation, and relative hypoxia operate alongside thermal stress to create a pro-oxidant testicular environment.[6,16] Experimental meta-analytic data also support increased malondialdehyde and higher SDF in varicocele models, consistent with oxidative injury as a central rather than incidental mechanism.[16]

Inflammation constitutes another significant source. Varicocele is increasingly recognised as a lesion that actively induces local inflammatory signalling, endothelial dysfunction, and heightened oxidative stress, rather than merely representing a passive venous anomaly. Leukocytes within semen are prominent producers of ROS, and even in the absence of overt infection, mild inflammatory activation can raise oxidative levels enough to adversely affect sperm membranes and chromatin integrity. This helps explain why some men with modest semen abnormalities carry disproportionate levels of functional impairment or DNA damage.[15,26]

A third source is sperm-associated and mitochondrial ROS generation. Varicocele has been linked to abnormal sperm retention, defective maturation, and the persistence of cytoplasmic residues in immature spermatozoa, all of which favor intracellular ROS production. Mitochondrial dysfunction then magnifies this signal, producing a feed-forward loop in which oxidative injury worsens mitochondrial performance and impaired mitochondria generate even more ROS.[6, 27] Importantly, these pathways need not act independently. In clinical varicocele, heat, hypoxia-like stress, inflammation, and mitochondrial dysfunction likely converge. The biological lesion is therefore not a single pathway but a redox network collapse in which multiple ROS sources become mutually reinforcing.

Oxidative stress biomarkers relevant to varicocele

Biomarker work in varicocele has evolved from direct ROS quantification toward broader characterization of oxidative damage and antioxidant failure. Traditional chemiluminescence-based assays measure seminal ROS directly and remain important in research because they capture oxidant activity itself. However, they are method-sensitive, require careful laboratory handling, and lack universal standardization, which is why guideline documents still regard routine ROS testing as experimental rather than fully established for universal practice.[28,29]

For that reason, indirect and composite markers have gained important. Malondialdehyde (MDA) remains one of the most frequently used indicators of lipid peroxidation and has relevance in varicocele because membrane injury is a prominent part of the phenotype. The meta-analysis by Cannarella *et al.* (2024)[8] specifically examined seminal MDA alongside SDF and found postoperative reductions after varicocele repair, supporting its utility as a biologically responsive marker in at least selected contexts. Total antioxidant capacity (TAC) is also widely studied, as it reflects the defensive side of the redox equation rather than oxidant burden alone. Meanwhile, 8-hydroxy-2'-deoxyguanosine (8-OHdG) has become especially attractive because it links oxidative chemistry directly to sperm DNA base damage, thereby connecting redox imbalance to genomic injury rather than only to membrane dysfunction.[30, 31]

Oxidation-reduction potential (ORP) was introduced to provide a more integrated snapshot of the balance between oxidants and antioxidants. Early multicenter data suggested diagnostic value in distinguishing abnormal from normal semen profiles, but recent studies have challenged its consistency and clinical interpretability, particularly when compared against validated oxidative-aggression markers.[32, 33] Thus, ORP is promising but not settled. In practice, no single biomarker fully captures the redox lesion in varicocele. A more defensible strategy is to interpret ROS, lipid peroxidation, DNA oxidation, TAC, and, where available, ORP as partially overlapping windows into a heterogeneous oxidative phenotype rather than as interchangeable tests.

Reductive oversimplification to avoid

The greatest conceptual error in this field is to equate OS with infertility in a one-step causal formula. OS is undeniably central to varicocele-associated testicular dysfunction, but centrality does not mean sufficiency. Many fertile men exhibit some degree of oxidative activity in semen, and not every man with clinical varicocele develops impaired fertility, elevated SDF, or a measurable reproductive penalty. OS should therefore be treated as a major mechanistic axis, not as a stand-alone diagnosis.[23] Its clinical meaning depends on magnitude, persistence, antioxidant reserve, concomitant inflammation, spermatogenic resilience, and the reproductive context of the couple.[6,16]

Another common mistake can be referred to as assay absolutism. Tests like ROS, ORP, MDA, TAC, and 8-OHdG each measure different aspects of biology. For example, direct ROS assays detect oxidants; ORP evaluates overall redox balance; MDA indicates lipid peroxidation; 8-OHdG identifies oxidative damage to DNA bases; TAC gauges antioxidant capacity. Relying on any single test as a stand-in for 'OS' can lead to misinterpretation. The EAU guidance explicitly notes the absence of standardized ROS testing methods and stops short of recommending routine ROS measurement in all infertile men, underscoring that the biomarker landscape remains informative but imperfect.[28] Recent data questioning the clinical usefulness of static ORP in idiopathic infertility further reinforce the need for caution.[33]

Furthermore, it is essential for the field to refrain from therapeutic simplification. If ROS serves physiological functions in sperm activity, then generalized increases in antioxidant administration do not constitute precision medicine; rather, such measures may substitute oxidative damage with reductive impairment. The biologically credible goal is restoration of the fertilization-relevant redox window, not maximal suppression of oxidants.[24,27] In varicocele, this means that biomarker interpretation and treatment decisions should be phenotype-driven, longitudinal where possible, and integrated with semen quality, SDF, and the reproductive timeline of the couple. The principal pathological issue is not the presence of ROS per se, but dysregulated redox biology that is oversimplified in clinical interpretation.

SPERM DNA FRAGMENTATION: BIOLOGY AND CLINICAL MEANING

Definition and forms of sperm DNA damage

SDF refers to structural discontinuities within the paternal genome of mature spermatozoa, but the term is often used too loosely. In strict biological terms, SDF is not a single lesion; it is an umbrella construct that encompasses single-strand breaks, double-strand breaks, alkali-labile sites, oxidative base modifications, and DNA discontinuities arising in the setting of defective chromatin packaging or incomplete nuclear remodeling during spermiogenesis.[3, 4] SDF therefore represents a final common pathway rather than a uniform mechanism. This distinction is important, as various initial insults can lead to comparable laboratory findings but may have distinct effects on reproduction and require different treatments.

As already mentioned, the sperm nucleus is biologically unique. During late spermiogenesis, histones are largely replaced by protamines, allowing extreme chromatin condensation and protection of the paternal genome. When this process is incomplete, regions of DNA remain less tightly packaged and become more susceptible to oxidative attack or nuclease-mediated cleavage. Some DNA lesions arise intratesticular during faulty chromatin remodeling or abortive apoptosis; others emerge after testicular release, particularly during epididymal transit or within seminal plasma exposed to OS and inflammation.[3, 34] In that sense, SDF is not merely a marker of 'broken DNA', but a readout of broader sperm nuclear vulnerability.

Clinically, this broader definition is essential because SDF may coexist with apparently acceptable concentration, motility, or morphology. Conventional semen analysis describes the visible phenotype of the ejaculated sperm population; SDF interrogates genomic integrity within that population. The two are related, but not interchangeable. This is precisely why recent guidelines and evidence summaries have treated SDF as a complementary functional biomarker rather than an extension of standard semen analysis.[3, 4] For a review focused on varicocele, the central point is that SDF captures the biological consequence of redox, thermal, inflammatory, and chromatin-level injury more directly than routine semen metrics alone.

Mechanistic origins of SDF in varicocele

In varicocele, SDF is best understood as the downstream genomic expression of a multifactorial testicular stress state. The lesion begins as venous reflux and pampiniform plexus dysfunction, but its reproductive impact is mediated through secondary disturbances in heat exchange, microcirculation, oxygen tension, inflammatory tone, and redox balance. These disturbances converge on the germ cell and on the maturing spermatozoon, where they promote oxidative DNA injury, defective chromatin stabilization, and in some cases apoptosis-related strand cleavage.[3, 9] SDF in varicocele is therefore not an isolated laboratory abnormality; it is the molecular residue of chronic biological disequilibrium.

OS appears to be the dominant mechanistic axis. Excess ROS can directly induce single- and double-strand breaks, oxidize DNA bases, and destabilize the nucleoprotein architecture that protects the paternal genome. This is particularly relevant in sperm because mature cells possess limited cytoplasmic antioxidants and minimal capacity for DNA repair. Varicocele intensifies this vulnerability by promoting hyperthermia, mitochondrial dysfunction, and inflammatory activation within the testicular and post-testicular environment. The resulting damage may arise at multiple stages: during spermatogenesis through faulty chromatin compaction, during epididymal transit through oxidative attack, or later in ejaculated sperm exposed to a pro-oxidant seminal milieu.[3, 35]

Recent meta-analytic evidence supports this framework. Men with varicocele show significantly higher SDF than controls, and the signal persists across multiple studies despite assay heterogeneity and clinical variability. Importantly, the association supports a mechanistic interpretation of varicocele that extends beyond simple deterioration of count or motility: genomic instability may be one of the clearest biological pathways by which a clinically palpable varicocele translates into impaired fertility, miscarriage risk, or assisted reproductive technology (ART) inefficiency.[9] Thus, in varicocele, SDF should be viewed neither as epiphenomenon nor as an optional research add-on, but as a plausible mechanistic bridge between a vascular lesion and reproductive failure.

Methods to assess SDF

The clinical expansion of SDF testing has been driven by four principal assay families: terminal deoxynucleotidyl transferase dUTP nick end labeling (TUNEL), sperm chromatin structure assay (SCSA), Comet assay, and sperm chromatin dispersion (SCD, or halo) testing. These methods do not measure exactly the same biological event, which is why direct comparison of thresholds across techniques is problematic. TUNEL detects DNA strand breaks by labeling free 3′-OH termini and is often regarded as biologically intuitive because it identifies actual breaks at the sperm-cell level. SCSA uses flow cytometry to quantify susceptibility of sperm DNA to acid-induced denaturation and reports a DNA fragmentation index (DFI); it is highly standardized in experienced laboratories but reflects chromatin instability as much as breakage per se. Comet assay provides single-cell electrophoretic assessment and can be performed under alkaline or neutral conditions, allowing sensitivity to different types of DNA lesions, although it is methodologically demanding. SCD evaluates the halo of dispersed DNA loops after denaturation and protein removal, offering practical accessibility but somewhat greater dependence on operator interpretation.[4, 36]

The main advantage of these tests is their ability to detect molecular sperm defects that standard semen analysis cannot identify. However, their results are not interchangeable as a high threshold in one test may not apply to another. Additionally, factors such as abstinence duration, laboratory skill, sample handling, and characteristics of the tested population can all affect outcomes. This is one reason why both guideline documents and subsequent critical assessments have urged clinicians to interpret SDF in an assay-specific and scenario-specific manner rather than as a universal binary marker.[3, 36]

For varicocele-associated infertility, this has practical consequences. A test that identifies elevated SDF may still be clinically useful even when exact numeric thresholds vary,

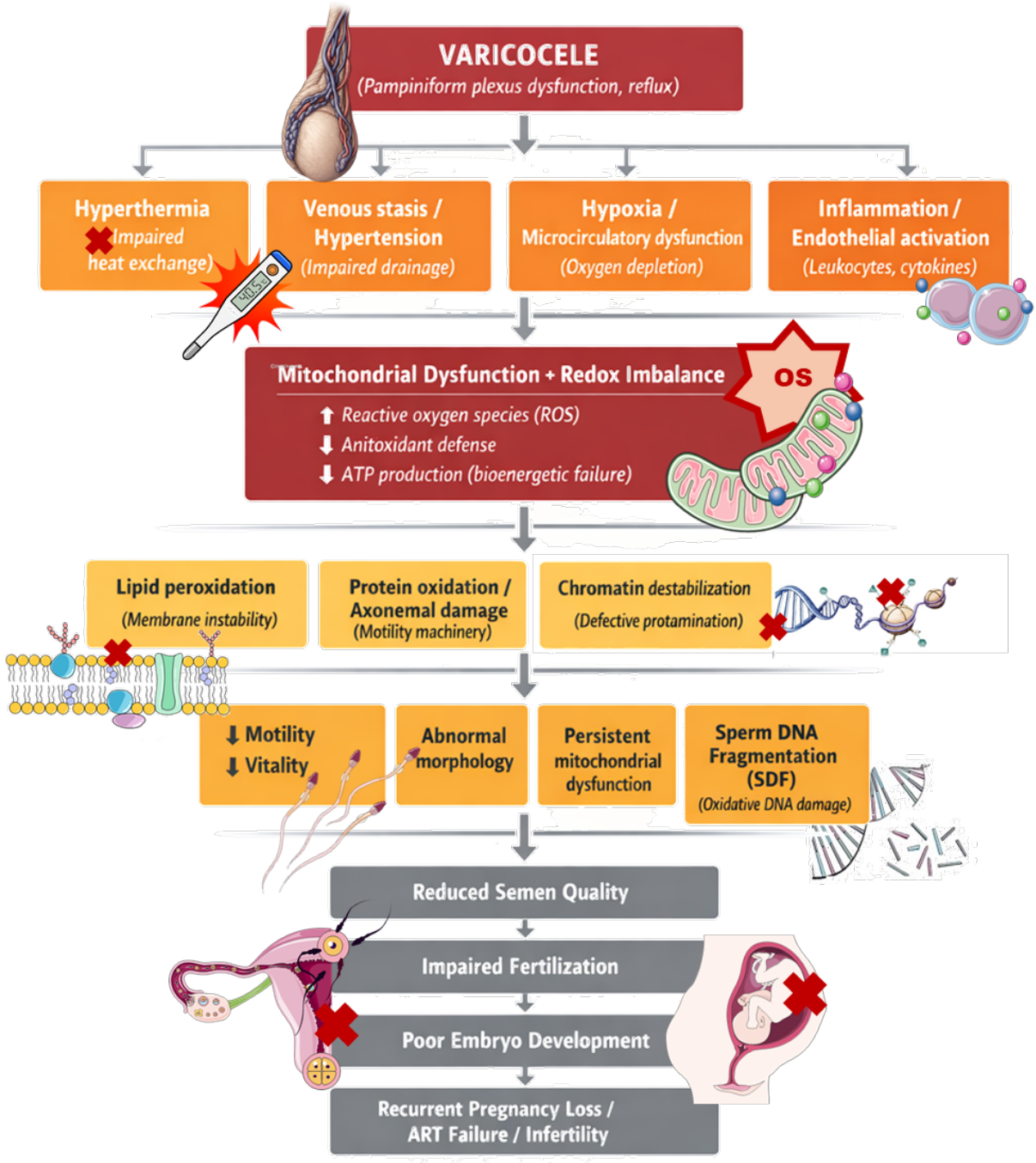

Figure 1. Mechanistic cascade linking varicocele to OS, SDF, and reproductive dysfunction.

provided interpretation is anchored to the assay platform, the patient phenotype, and the reproductive question being asked. The objective is not to seek a universally applicable cut-off, but to apply validated methods to identify biologically meaningful genomic injury in selected men whose fertility phenotype is insufficiently explained by semen analysis alone.[37] That is the level at which SDF testing becomes translational rather than merely descriptive.

Clinical significance of elevated SDF

The clinical importance of elevated SDF lies in its repeated association with adverse reproductive outcomes across natural conception and assisted reproduction settings. Evidence syntheses and practice recommendations have consistently linked high SDF with reduced chances of spontaneous pregnancy, particularly in couples classified as unexplained or in men whose routine semen profile appears only mildly abnormal. The biological explanation is credible: even when a spermatozoon reaches and fertilizes the oocyte, excessive paternal DNA damage can compromise early embryogenesis, increase developmental arrest, or shift the burden of repair to the oocyte beyond its compensatory capacity.[3, 4]

The miscarriage signal is especially important. Elevated SDF has been associated with recurrent pregnancy loss and with poorer reproductive efficiency after both natural and assisted conception. This does not mean SDF acts in isolation, but it does suggest that paternal genomic quality contributes more to reproductive attrition than traditional semen analysis alone can reveal. In IVF and ICSI settings, the literature is more heterogeneous, yet the overall direction remains clinically relevant: high SDF has been linked to impaired fertilization, poorer embryo development in some cohorts, and a greater risk of pregnancy loss, even if effect sizes differ by female age, oocyte competence, assay method, and treatment strategy.[4, 34]

This is why recent guidelines do not recommend universal SDF testing, but they do support its use in selected scenarios such as recurrent pregnancy loss, unexplained infertility, clinical varicocele, repeated ART failure, and apparently normal semen profiles discordant with poor reproductive outcomes.[3, 38] For varicocele in particular, SDF has special value because it explains a common clinical puzzle: why some men with modest conventional semen abnormalities exhibit disproportionate infertility or repeated reproductive failure. In that context, SDF becomes more than a laboratory number. It becomes a clinically meaningful indicator that the lesion has progressed from a visible venous abnormality to a genomically consequential male-factor disorder.

OXIDATIVE STRESS-SDF-VARICOCELE AXIS

Mechanistic model

The OS-SDF-varicocele axis is best understood as a biologically ordered cascade rather than as three loosely associated observations (**Figure 1**). Varicocele is the upstream lesion, but its reproductive relevance emerges only when venous reflux and pampiniform plexus dysfunction disrupt the local testicular environment sufficiently to trigger oxidative, thermal, hypoxic, and inflammatory stress. Current reviews consistently support this integrated view: impaired countercurrent heat exchange elevates scrotal and intratesticular temperature; venous hypertension and sluggish outflow disturb microcirculation; relative hypoxia and endothelial dysfunction enhance ROS generation; and inflammatory signaling amplifies the pro-oxidant milieu. The resulting redox imbalance is not a benign biochemical shift but a systems-level threat to spermatogenesis, sperm maturation, and sperm nuclear stability.[2, 6] Within this network, spermatozoa occupy a uniquely fragile position. Their membranes are rich in polyunsaturated fatty acids, their antioxidant reserves are limited, and their post-meiotic DNA repair capacity is minimal. Once ROS

Table 1. Biological cascade linking varicocele to oxidative stress, sperm DNA fragmentation, and reproductive dysfunction.

Upstream biological disturbance in varicocele	Principal pathophysiological effect	Dominant oxidative / genomic consequence	Functional sperm / semen correlate	Candidate biomarker(s) / assay(s)	Key supporting references
Impaired pampiniform plexus function and defective countercurrent heat exchange	Chronic scrotal and intratesticular hyperthermia	Increased ROS generation; protein and membrane injury	Reduced motility, vitality, fertilizing competence	ROS assays, ORP, MDA	Wood et al., 2021; Lira et al., 2024; Wang et al., 2022
Venous reflux, venous hypertension, and blood stasis	Disturbed microcirculation and testicular metabolic stress	Oxidative amplification and impaired cellular homeostasis	Lower sperm concentration and total count	ROS, TAC, ORP	Lira et al., 2024; Munoz-Lopez et al., 2024; Wang et al., 2025
Relative hypoxia / reperfusion-like injury	Mitochondrial stress and inefficient ATP generation	Mitochondrial ROS excess; oxidative damage to lipids and DNA	Poor progressive motility, reduced vitality	ROS, MDA, mitochondrial function indices	Russo et al., 2024; Wang et al., 2022
Inflammatory activation and endothelial dysfunction	Cytokine-driven oxidative amplification; leukocyte-derived ROS	Membrane lipid peroxidation and chromatin injury	Poor motility; increased dysfunctional sperm fraction	ROS, inflammatory mediators, TAC, SDF assays	Wang et al., 2025; Ritchie and Ko, 2021
Persistence of immature sperm / cytoplasmic retention	Enhanced intracellular ROS production	Oxidative membrane injury and DNA instability	Abnormal morphology; impaired motility	ROS, MDA, SDF assays	Lira et al., 2024; Wright et al., 2014
Defective chromatin remodeling / incomplete protamination	Reduced genomic compaction and nuclear resilience	Increased susceptibility to oxidative base damage and strand breaks	Normal or mildly abnormal semen with hidden genomic damage	TUNEL, SCSA, Comet, SCD	Agarwal et al., 2020; Andrabi et al., 2024; Esteves et al., 2021
Excess ROS beyond physiological redox window	Failure of redox homeostasis	Lipid peroxidation, oxidative base damage, DNA fragmentation	Global decline in sperm functional competence	ROS, ORP, MDA, 8-OHdG, TAC	Dutta et al., 2019; Symeonidis et al., 2021; Mottola et al., 2024
Oxidative DNA base damage and strand breaks	Genomic instability in ejaculated spermatozoa	Elevated SDF	Reduced natural conception; poorer ART efficiency; higher miscarriage risk	TUNEL, SCSA, Comet, SCD	Agarwal et al., 2020; Esteves et al., 2021; Wan et al., 2026
Integrated downstream phenotype	Decompensated redox-inflammatory-genomic state	High SDF with or without major routine semen abnormality	Infertility, recurrent pregnancy loss, ART failure	Combined semen analysis + SDF ± OS testing	Lira et al., 2024; Palani et al., 2025; Kaltsas et al., 2026

rises beyond the fertilization-permissive range, lipid peroxidation, mitochondrial dysfunction, oxidative base injury, and chromatin destabilization begin to develop in parallel. SDF thus becomes a downstream readout of cumulative injury rather than an isolated event. In varicocele, this damage may originate during spermiogenesis through defective chromatin remodeling, during epididymal transit through oxidative attack, or after ejaculation within a seminal environment already biased toward oxidative injury.[6]

This model has an important interpretive consequence (**Table 1**). It explains why varicocele severity cannot be judged solely by venous caliber or by conventional semen analysis. A visible venous abnormality becomes clinically consequential when it generates a molecular phenotype characterized by oxidative overload and genomic instability. In this sense, SDF is not merely associated with varicocele; it is one of the most coherent downstream biological expressions of a decompensated varicocele state. That mechanistic continuity is what makes the axis translationally useful, because it links anatomy to reproductive outcome through a plausible intermediate biology rather than through descriptive correlation alone.[6, 8]

Evidence linking varicocele to elevated SDF

The evidence linking varicocele with elevated SDF has strengthened considerably with recent systematic reviews and meta-analyses. The most direct synthesis is the 2025 systematic review and meta-analysis by Palani et al., which examined men with varicocele versus men without varicocele and found significantly higher SDF among those with varicocele, alongside poorer semen parameters. The consistency of the direction of effect across studies is notable because the included literature spans different assays, populations, and clinical settings. That heterogeneity limits precision, but it does not erase the central finding: men with varicocele tend to carry a greater burden of sperm genomic injury than comparator groups without the lesion.[9] Equally important is the interventional evidence. The 2024 systematic review and meta-analysis by Cannarella et al. evaluated infertile men with clinical varicocele before and after varicocele repair and found significant postoperative reductions in SDF and seminal MDA, a commonly used marker of lipid peroxidation. This matters because it moves the field beyond cross-sectional association. If varicocele repair lowers both oxidative damage markers and SDF, the relationship is more difficult to dismiss as incidental. The data do not prove that every man with varicocele will benefit, nor do they resolve the assay-standardization problem, but they strongly support a biologically responsive link between the lesion, OS, and sperm DNA integrity.[8]

Recent guideline-era reviews have therefore begun to frame SDF as particularly relevant in selected men with clinical varicocele, especially when the infertility phenotype seems disproportionate to routine semen results, when recurrent pregnancy loss is part of the couple history, or when prior ART has failed without a clear male explanation. The evidence is not a mandate for universal testing, but it is sufficient to justify considering SDF as a mechanistically anchored adjunct in the evaluation of varicocele-associated infertility.[2, 6]

Conceptual importance

The real importance of the OS-SDF-varicocele axis is conceptual before it is procedural. It changes the clinical meaning of varicocele from a simple venous finding to a biologically stratified disease state. In the older framework, varicocele was judged primarily by palpability, grade, and conventional semen abnormalities. In the newer framework, those features remain relevant but are no longer sufficient. The decisive question becomes whether the lesion has generated a pathogenic redox and genomic phenotype. This shift matters because it explains one of the most persistent clinical paradoxes in andrology: some men with clinically evident varicocele remain fertile, whereas others with seemingly modest semen abnormalities experience infertility, miscarriage, or ART failure. The axis provides a mechanistic explanation for that discordance by identifying oxidative burden and SDF as intermediates between anatomy and reproductive failure.[6, 9]

This conceptual reframing also sharpens decision-making. If SDF is elevated in a man with clinical varicocele, the lesion can no longer be treated as a visually apparent but biologically ambiguous abnormality. It has already declared downstream molecular consequences. That does not automatically dictate surgery, but it does alter the weight of evidence when counseling couples, especially those with unexplained infertility, recurrent pregnancy loss, or prior ART inefficiency. In this setting, SDF becomes more than an ancillary biomarker; it becomes a bridge between mechanism and management.[2, 8]

Finally, the axis helps reclassify part of so-called idiopathic male infertility. Some men labeled idiopathic may in fact harbor clinically relevant varicocele-associated oxidative and genomic injury that routine semen analysis does not adequately capture. That possibility is precisely why current reviews increasingly call for phenotype-directed assessment rather than anatomical description alone. The translational value of the axis, therefore, lies not only in explaining pathophysiology but in supporting a more credible precision-andrology model, in which treatment is guided by demonstrable biological disturbance rather than by the presence of dilated veins alone.[6, 8, 9]

DIAGNOSTIC WORK-UP: FROM CONVENTIONAL EVALUATION TO MOLECULAR PHENOTYPING

Standard male infertility work-up

The diagnostic evaluation of suspected varicocele-associated infertility should begin with assessment of the infertile couple as a whole, rather than with isolated consideration of the scrotal finding. Current AUA/ASRM guidance emphasizes concurrent assessment of both partners and recommends a focused male work-up built on reproductive history, sexual history, developmental history, systemic illness, prior paternity, medications, toxicant exposure, surgery, and febrile or endocrine events, followed by directed physical examination and at least one semen analysis, with repeat testing when needed because semen variables fluctuate over time. Physical examination remains a core component of evaluation, as testicular volume, consistency, epididymal fullness, vas deferens status, secondary sexual characteristics, and the presence and grade of a palpable varicocele all influence subsequent clinical decision-making.[1, 2]

Semen analysis remains the gateway test, but it should not be mistaken for a complete biological assessment. Guideline-era practice still uses semen concentration, motility, morphology, and volume as the first-line laboratory framework, yet both AUA/ASRM and EAU-linked recommendations make clear that semen analysis alone cannot fully define male reproductive competence. Hormonal evaluation is indicated when clinical features suggest endocrine dysfunction or when sperm concentration is markedly reduced, and genetic testing enters the pathway in more severe oligozoospermia or azoospermia. Scrotal ultrasonography is not recommended as a routine substitute for physical examination in the initial infertility work-up, but it has a role when the examination is equivocal, when recurrence is suspected, or when other scrotal pathology must be clarified.[1, 2]

For varicocele specifically, this standard work-up serves two purposes. First, it confirms whether the lesion is clinically meaningful in the context of infertility. Second, it identifies discordance: men with palpable varicocele may show severe semen impairment, mild abnormalities, or even apparently acceptable routine semen profiles despite poor reproductive outcomes. That mismatch is the point at which conventional evaluation reaches its limit and molecular phenotyping becomes attractive. Thus, the standard work-up should not be bypassed in favor of biomarkers; rather, it should be used to define the clinical phenotype precisely enough to know when biomarkers are likely to add value.[1, 6]

When to suspect an oxidative-SDF predominant varicocele phenotype

An oxidative-SDF predominant phenotype should be suspected when the clinical consequences of varicocele appear greater than routine semen analysis can reasonably explain. This includes the man with a palpable varicocele and only mild semen abnormalities despite prolonged infertility, the couple with recurrent pregnancy loss in whom female factors do not sufficiently account for reproductive failure, and the setting of repeated ART inefficiency or poor embryogenesis without an obvious alternative male diagnosis. EAU guidance now explicitly states that varicocelectomy may be considered in men with raised SDF and otherwise unexplained infertility, including cases marked by ART failure, implantation failure, or recurrent pregnancy loss. That recommendation is weak rather than universal, but its presence is important: it reflects recognition that varicocele can become biologically consequential through genomic injury even when routine semen metrics are not dramatic.[2]

The suspicion should be even stronger when the lesion coexists with known oxidative amplifiers such as smoking, obesity, metabolic dysfunction, genital tract inflammation, febrile stress, occupational heat exposure, or prolonged abstinence patterns, because these may convert a compensated varicocele into a decompensated redox phenotype.[39-41] The recent varicocele-focused review by Lira et al. frames this particularly well: varicocele should be viewed not as an isolated venous abnormality, but as a biological stressor whose downstream effects are magnified by thermal imbalance, hypoxia-like stress, oxidative damage, and inflammation. In that framework, SDF is not a separate disorder but one of the most meaningful downstream expressions of the lesion's pathogenic activity.[6]

A practical clue is clinical disproportion. When a grade II-III palpable varicocele is present, the couple has a significant infertility history, yet semen analysis appears only borderline abnormal, or when previous ART attempts have failed despite apparently usable ejaculated sperm, one should ask whether the unmeasured problem is genomic rather than merely quantitative. That does not mean every such patient requires immediate molecular testing. It indicates that apparently near-normal semen findings should not be interpreted as evidence of biological reassurance. In selected men, the real lesion may be oxidative chromatin injury, and failure to recognize that possibility risks underestimating the reproductive impact of varicocele.[6, 38]

Where oxidative stress tests and SDF fit in practice

Current evidence does not support indiscriminate OS testing or universal SDF assessment in all infertile men with varicocele. The strongest contemporary position is selective use. AUA/ASRM guidance does not recommend SDF as a routine first-line test for the initial evaluation of every infertile male, whereas recent EAU-linked guidance and other contemporary expert-consensus recommendations recognize clinically relevant scenarios in which SDF testing may refine management. These include recurrent pregnancy loss, unexplained infertility, repeated ART failure, and clinically meaningful varicocele when the reproductive phenotype appears disproportionate to conventional semen findings.[1, 2, 38]

This selective positioning is biologically sound. OS assays and SDF tests are not replacements for semen analysis, history, or examination; they are second-line tools designed to reveal hidden functional injury when first-line data are incomplete. SDF has a clearer clinical foothold than direct OS testing because its associations with miscarriage, unexplained infertility, and varicocele-related genomic injury are better developed and more consistently addressed in consensus documents.[42] OS tests, by contrast, remain attractive but less standardized, and current guidelines stop short of endorsing them for widespread routine use because assay comparability and threshold definition remain unsettled.[6, 38]

In practice, the most defensible model is layered diagnostics. First-line evaluation identifies the clinical context: infertility duration, female partner age and reserve, palpable varicocele, semen profile, and endocrine background. Second-line molecular testing is then reserved for men in whom one of two questions arises: does the lesion have hidden biological severity, or would evidence of genomic injury change treatment sequencing? If the answer is yes, SDF testing may strengthen the rationale for varicocelectomy, intensify counseling, or alter the timing and selection of ART strategies. Used in this manner, molecular tests do not unnecessarily complicate the evaluation; rather, they reduce the risk of false reassurance based on incomplete first-line findings. The goal is not to create a biomarker-heavy algorithm, but to identify the men in whom routine andrology misses the true depth of sperm dysfunction.[1, 6, 38]

Proposed diagnostic phenotypes

A phenotype-based diagnostic framework is more useful than a purely anatomical one because it acknowledges that palpable varicocele does not behave as a single disease state. At least four clinically relevant phenotypes can be proposed. The first is the

'*conventional semen-predominant phenotype'*: palpable varicocele, abnormal semen parameters, and infertility with no major molecular ambiguity. This is the traditional candidate for varicocele repair and remains strongly aligned with current guideline recommendations. The second is the '*high-SDF/near-normal semen phenotype'*, in which routine semen analysis offers partial reassurance but the couple history suggests otherwise, prolonged infertility, recurrent pregnancy loss, or repeated ART inefficiency. This is the phenotype in which molecular testing is most likely to change the clinical reading of varicocele.[1, 2]

A third category is the '*oxidative-inflammatory phenotype'*, characterized by varicocele plus coexisting pro-oxidant or inflammatory burdens such as smoking, obesity, metabolic dysfunction, leukocytospermia, genital tract inflammation, or heat exposure. Here, varicocele is unlikely to be acting alone; instead, it is one contributor to a broader redox network collapse. The fourth is a '*mixed mitochondrial-chromatin injury phenotype'*, in which reduced motility, poor vitality, repeated fertilization failure, or elevated SDF suggest that mitochondrial dysfunction and genomic injury coexist. Recent reviews of varicocele pathophysiology support this layered view, emphasizing that the lesion can express itself through oxidative, inflammatory, and chromatin-level injury rather than through count and motility alone.[6]

The value of this classification is practical rather than taxonomic. It encourages clinicians to ask not simply 'Is there a varicocele?' but 'What kind of varicocele biology is this patient expressing?' That question matters because it determines whether conventional management is adequate or whether molecular phenotyping is needed to expose hidden disease severity. In a precision-andrology model, phenotype directs escalation: standard repair pathway for the semen-predominant group, targeted SDF assessment for the discordant group, and broader lifestyle-inflammatory correction plus selected biomarker use for oxidative-inflammatory states. Such a framework is not yet a formal guideline table, but it is fully consistent with where the evidence is moving, away from anatomy alone and toward biologically informed patient stratification.[2, 6, 38]

CLINICAL CONSEQUENCES OF THE OXIDATIVE-SDF BURDEN IN VARICOCELE

Effects on semen quality

The first clinical expression of the oxidative-SDF burden in varicocele is usually deterioration of conventional semen quality, but the pattern is neither uniform nor mechanistically simple. Recent meta-analytic evidence indicates that men with varicocele have significantly higher SDF than controls and, in parallel, exhibit lower sperm concentration, lower total sperm count, reduced vitality, poorer total and progressive motility, and worse morphology. In the 2025 systematic review and meta-analysis by Palani et al., the pooled signal was directionally consistent across these domains, supporting the view that varicocele affects semen quality at multiple biological levels rather than through a single isolated parameter.[9]

Mechanistically, this broad impairment is plausible. OS does not act only on DNA. It damages membrane lipids, perturbs axonemal proteins, compromises mitochondrial energy production, and destabilizes chromatin packaging, thereby linking impaired motility, reduced vitality, and genomic injury within the same sperm population. The key clinical implication is that conventional semen impairment and SDF are related but non-redundant consequences of the same redox-disturbed environment. This explains why some men with varicocele show marked semen abnormalities together with high SDF, while others display only modest changes in count or motility despite substantial chromatin damage.[6]

That distinction matters diagnostically. Conventional semen analysis remains indispensable, but it reflects the visible phenotype of ejaculated sperm, not the full extent of molecular injury. Palani et al. explicitly note that SDF provides independent information and appears more stable than conventional semen parameters, supporting combined interpretation rather than substitution. In practice, a varicocele-associated decline in semen quality should therefore be read as the surface manifestation of a deeper biological lesion; the more severe the oxidative burden, the less defensible it becomes to interpret sperm count and motility alone as sufficient markers of reproductive competence.[6, 9]

Effects on fertilization and embryo competence

The oxidative-SDF burden in varicocele has consequences that extend beyond semen quality into the earliest stages of reproduction. Once sperm DNA damage rises above the threshold that can be compensated by the oocyte, fertilization may still occur, but embryo competence becomes less secure. Recent expert synthesis and meta-analytic overviews indicate that elevated SDF is associated with poorer reproductive efficiency, including impaired natural conception, reduced success in intrauterine insemination, and adverse effects on assisted reproduction outcomes, particularly in conventional IVF. The biological rationale is straightforward: oxidative and chromatin injury can compromise paternal genome delivery, post-fertilization repair dynamics, and early embryonic development, even when a spermatozoon appears usable under standard laboratory assessment.[35, 43]

For ART, the evidence is important but must be read critically. The 2026 umbrella meta-analysis by Wan et al. concluded that elevated SDF is associated with reduced clinical pregnancy in IVF and IUI, while the association in ICSI is weaker and less consistent; miscarriage risk, however, appears increased across ART, particularly in ICSI. The same review judged the certainty of evidence as low because the literature remains heterogeneous with respect to assay platform, patient selection, and study quality. Thus, high SDF is better viewed as a probabilistic adverse factor than as a deterministic predictor of ART failure.[43]

This nuance is especially relevant in varicocele. If the lesion generates oxidative genomic injury, the clinical problem is not merely low motility or lower fertilization potential, but reduced embryo robustness. Lira et al. argue that SDF may partly explain why varicocele can impair reproductive outcomes even when basic semen parameters are only mildly abnormal. Accordingly, the oxidative-SDF burden should be regarded as a biologically credible pathway through which varicocele reduces fertilization efficiency and compromises embryo developmental competence, rather than as an incidental laboratory abnormality.[6]

Effects on miscarriage and recurrent reproductive failure

Among all downstream consequences of SDF, miscarriage and recurrent reproductive failure are arguably the most clinically consequential. The association is now sufficiently consistent that recent expert guidelines and reviews no longer treat it as speculative. A recent expert consensus guideline states that SDF has a defined role in the evaluation of recurrent pregnancy loss (RPL), citing meta-analyses that show significantly higher SDF levels in male partners of couples with RPL than in fertile controls. That document also notes that both AUA/ASRM and EAU guidance recognize a strong association between RPL and elevated SDF, although not as a stand-alone explanation in every case.[38]

The ART literature points in the same direction, though again with necessary caution. Wan et al. found that high SDF is associated with increased pregnancy loss in ART, with the strongest signal observed in ICSI, while Li et al., in a large retrospective ART cohort, reported a positive relationship between DFI and miscarriage rate and a negative relationship with birth weight. These findings reinforce the plausibility that paternal DNA damage affects not only conception but also post-implantation viability; however, both studies underscore the need for prospective validation and standardized testing before these associations are translated into rigid clinical thresholds.[43, 44]

In varicocele, this consequence is particularly important because the lesion may otherwise be underestimated as a 'minor' male factor. Lira et al. note that elevated SDF in varicocele is linked to lower chances of natural conception and poorer ART success, and that postoperative reductions in SDF have been associated in several cohorts with higher pregnancy rates. The inference is not that every miscarriage in a couple with varicocele is sperm-driven; it is that varicocele-associated oxidative genomic injury may be one of the most credible paternal contributors to recurrent reproductive failure, especially when female causes are insufficient to explain the phenotype.[6]

Implications for couple counseling

The counseling implications of this evidence are substantial. First, a clinically detectable varicocele should not be discussed with couples only in terms of venous anatomy or routine semen numbers. Recent varicocele-focused synthesis supports a biologically grounded interpretation: in some men, varicocele behaves as an oxidative-genomic disorder, and the visible lesion may underestimate its reproductive significance. This is why 'mild' semen abnormalities do not necessarily indicate mild biological disease, and why couples with prolonged infertility, recurrent pregnancy loss, or failed ART may require a deeper conversation about hidden sperm dysfunction.[6, 9]

Second, counseling must be selective rather than alarmist. The same evidence base that supports clinical relevance also warns against overinterpretation. A recent expert-consensus guideline emphasizes tailored use of SDF testing rather than universal testing, because clinically meaningful evidence coexists with persistent gaps in assay standardization and outcome prediction. Similarly, the umbrella ART review by Wan et al. concludes that the overall certainty of evidence remains low despite recurrent associations with adverse outcomes. Couples should therefore be told that elevated SDF increases concern, but does not guarantee infertility, miscarriage, or ART failure.[38, 43]

Finally, counseling should shift from reassurance based on 'normal-looking semen' toward explanation grounded in phenotype. A man with palpable varicocele, borderline semen parameters, and a history of repeated reproductive failure should not be told that the male factor is negligible simply because concentration or morphology is near reference limits. In such couples, the clinically relevant question is whether OS and SDF have converted an anatomical lesion into a functionally significant male-factor disorder. That reframing helps couples understand why additional testing, varicocele repair, modification of coexisting oxidative exposures, or altered ART strategy may be justified in selected cases.[6, 38]

VARICOCELE REPAIR AND ITS BIOLOGICAL EFFECTS

Current indications for varicocele treatment

The modern indication for varicocele repair is not the mere detection of dilated veins, but the demonstration of a clinically meaningful lesion within an infertile couple context. The 2024 AUA/ASRM amended guideline states that clinicians should consider surgical varicocelectomy in men attempting conception who have palpable varicocele(s), infertility, and abnormal semen parameters, while explicitly advising against repair for non-palpable varicoceles detected solely by imaging.[1] The 2025 EAU update retains the same core position, recommending treatment in infertile men with a clinical varicocele, abnormal semen parameters, and otherwise unexplained infertility, particularly when the female partner has good ovarian reserve and the goal is to improve fertility rates.[2]

What has changed in recent years is not the abandonment of conventional indications, but their biological expansion. The EAU now further states that varicocelectomy may be considered in men with elevated SDF and otherwise unexplained infertility, as well as in those with assisted reproduction failure, including recurrent pregnancy loss, implantation failure, or failed embryogenesis. This is a weak recommendation, but an important one, because it acknowledges that varicocele may be clinically relevant even when routine semen analysis incompletely reflects the depth of sperm injury.[2] In parallel, recent reviews have argued that repair decisions should increasingly incorporate OS-linked phenotypes, especially in men whose infertility appears disproportionate to standard semen findings.[6]

Thus, the most defensible indication framework is layered. The traditional candidate remains the infertile man with a palpable varicocele and abnormal semen profile. Beyond that, selected men with elevated SDF, repeated reproductive failure, or a discordant infertility phenotype may also merit consideration, provided that counseling remains transparent about the weaker evidence base in these scenarios. In other words, repair is no longer justified solely by anatomy, but neither should it be restricted to anatomy alone. The field is moving toward a phenotype-guided model in which varicocele is treated when it behaves as an active biological disease rather than as a passive venous finding.[1, 2, 6]

Effect of varicocelectomy on oxidative stress

One of the strongest biological arguments for varicocele repair is that it appears to reduce the oxidative burden generated by the lesion. This is important because the mechanistic relevance of varicocele does not lie in venous dilatation per se, but in the oxidative, thermal, inflammatory, and hypoxic stress that follows from pampiniform plexus dysfunction. If repair restores more favorable testicular hemodynamics and heat exchange, a reduction in oxidative injury should be one of the earliest measurable consequences. Recent evidence supports exactly that interpretation. The 2024 systematic review and meta-analysis by Cannarella et al. found that varicocele repair was associated with a significant reduction in seminal MDA, a widely used lipid peroxidation marker, in infertile men with clinical varicocele. Because MDA reflects oxidative membrane injury rather than simple semen quantity, its postoperative fall suggests true biological modification of the seminal redox environment rather than only numerical improvement in semen parameters.[8]

This finding fits well with recent review-level pathophysiology. Contemporary syntheses describe varicocele as a redox-amplifying lesion in which hyperthermia, venous stasis, disturbed oxygen handling, leukocyte activation, and mitochondrial dysfunction generate a sustained oxidative milieu. Varicocelectomy, in that framework, is not merely corrective surgery; it is an intervention aimed at interrupting a biologically self-reinforcing circuit. Lira et al. emphasized that the relevance of repair lies partly in its capacity to attenuate OS and thereby modify downstream sperm injury pathways, including membrane dysfunction and DNA damage.[6]

The evidence, however, should not be oversold. OS biomarkers are not fully standardized, and not all studies assess the same markers, time points, or patient phenotypes. A postoperative reduction in MDA is compelling, but it is not identical to proving restoration of normal redox physiology in every patient. The more careful conclusion is that varicocelectomy appears capable of shifting the seminal environment in a less oxidative direction, and that this redox improvement is biologically plausible, measurable, and clinically relevant. It also provides one of the clearest mechanistic bridges between surgery and later improvement in sperm DNA integrity or fertility outcomes.[6, 8]

Effect of varicocelectomy on SDF

Among the biological effects of varicocele repair, reduction in SDF is one of the most clinically consequential. Cross-sectional evidence already supports that men with varicocele have higher SDF than men without the lesion, but interventional evidence is what gives this observation translational weight. The 2024 systematic review and meta-analysis by Cannarella et al. showed a significant postoperative decline in SDF after varicocele repair in infertile men with clinical varicocele. That matters because SDF is not simply another semen variable; it is a downstream marker of cumulative oxidative and chromatin-level injury. A reduction after surgery therefore suggests that repair modifies one of the lesion's most important molecular consequences rather than merely improving count or motility in a cosmetic way.[8]

More recent literature has reinforced this interpretation. The 2025 systematic review and meta-analysis by Palani et al. confirmed that varicocele is associated with substantially higher SDF overall and highlighted the clinical rationale for incorporating SDF into the diagnostic and therapeutic evaluation of selected men with varicocele. Although that review was not itself a treatment meta-analysis, it strengthened the conceptual basis for why postoperative SDF improvement matters: SDF captures the genomic burden that may explain infertility in men whose routine semen results provide only partial explanation.[9] A 2025 evidence synthesis comparing treatment strategies similarly reported improvement in SDF after repair, again suggesting that SDF is a responsive biological endpoint rather than a static trait.[45]

Still, three cautions are necessary. First, SDF assays are not interchangeable; absolute thresholds vary by platform. Second, not every patient shows the same magnitude of postoperative improvement, which likely reflects heterogeneity in age, baseline semen impairment, disease duration, bilateral disease, oxidative co-exposures, and female-factor context. Third, biomarker improvement is valuable only insofar as it informs reproductive decision-making. The best conclusion, therefore, is not that varicocelectomy 'normalizes' DNA integrity, but that it often reduces a major molecular burden and thereby improves the biological quality of the ejaculated sperm population. This is precisely why contemporary guidelines now allow consideration of repair in selected men with elevated SDF and otherwise unexplained infertility or ART failure.[2, 8]

Effect on reproductive outcomes

The ultimate justification for varicocele repair is not biochemical elegance but reproductive benefit. Here, the evidence is supportive, though necessarily more heterogeneous than biomarker studies. The 2025 EAU update recommends treating infertile men with a clinical varicocele, abnormal semen parameters, and otherwise unexplained infertility to improve fertility rates, especially when the female partner has good ovarian reserve. That recommendation reflects accumulated evidence that correction of palpable varicocele can improve semen quality and, in selected populations, increase the probability of natural conception.[2] The AUA/ASRM update similarly recognizes improved semen quality and fertility after correction of palpable lesions, while continuing to reject repair of non-palpable, imaging-only varicoceles.[1]

The biological literature makes these outcome gains more intelligible. If repair lowers OS and reduces SDF, improved fertility should not be interpreted simply as the consequence of higher sperm counts. It may also reflect improved sperm genomic competence, better embryo robustness, and possibly lower reproductive attrition. Recent varicocele-focused reviews have therefore argued that the value of repair extends beyond standard semen improvement to a broader restoration of sperm functional integrity.[6] This is particularly relevant in couples with otherwise unexplained infertility, recurrent pregnancy loss, or repeated ART inefficiency, where genomic sperm injury may have been underestimated before repair.[2, 6]

Yet outcome interpretation must remain disciplined. Not every man benefits, spontaneous pregnancy depends heavily on female age and couple-level factors, and the evidence for ART-specific gains is less uniform than the evidence for biomarker improvement. That is why the EAU frames SDF-driven indications as 'may be

considered' rather than routine. The clinically sound position is that varicocelectomy can improve reproductive outcomes in appropriately selected men, and that the most persuasive biological substrate for this benefit is postoperative reduction in oxidative injury and SDF. Surgery should therefore be presented neither as an automatic fertility cure nor as a purely semen-improving procedure, but as a mechanism-directed intervention whose outcome value depends on selecting the right phenotype at the right time.[1, 2, 8]

BEYOND SURGERY: ADJUNCTIVE AND PRECISION MANAGEMENT

Lifestyle and exposure modification

Adjunctive management in varicocele should begin with an uncomfortable but necessary truth: surgery corrects venous anatomy, not the full oxidative ecology in which sperm mature and function. A man with repaired varicocele may still carry smoking-related oxidative injury, obesity-linked inflammation, sleep disruption, excessive heat exposure, genital tract inflammation, metabolic dysfunction, or prolonged abstinence patterns that continue to sustain SDF.[46, 47] The 2025 EAU male infertility guidance explicitly notes that SDF can be increased by lifestyle factors, including smoking, in addition to varicocele and chronic infection, and also reports that repeated ejaculation separated by a three-hour interval has been shown to decrease SDF in selected settings.[2, 28, 48] That position is clinically important because it shifts management from lesion-centered thinking to burden-centered thinking: varicocele is one generator of OS, but rarely the only one.

The interventional logic is therefore straightforward. In men with varicocele-associated infertility, cessation of smoking, reduction of scrotal heat load, optimization of body weight and metabolic status, treatment of genital tract inflammation where present, and rational adjustment of ejaculation timing are not generic lifestyle sermons; they are attempts to reduce post-testicular and systemic contributors to oxidative sperm injury. A 2023 systematic review and meta-analysis found that multiple lifestyle, environmental, and health factors are associated with increased SDF, reinforcing that DNA damage in sperm often reflects cumulative exposure biology rather than a single isolated diagnosis.[49] More recent synthesis has further evaluated lifestyle modification among the interventions capable of influencing SDF, although the interventional evidence remains less robust than the association data.[45]

What should be avoided is false precision. Not every infertile man with varicocele requires an elaborate lifestyle program, and not every modifiable exposure has equal biological weight. The more defensible precision approach is to identify coexisting oxidative amplifiers and correct those most plausibly linked to the patient's phenotype. In practice, this means that lifestyle modification is not an 'alternative' to varicocele repair; it is the necessary second half of management in any patient whose oxidative-SDF burden is unlikely to be explained by venous disease alone.

Antioxidant therapy

Antioxidant therapy occupies an uneasy space in male infertility: biologically plausible, clinically popular, but evidentially unstable. The rationale is readily understandable. If varicocele contributes to sperm injury through OS, then targeted antioxidant treatment seems rational. Meta-analytic literature has reported improvements in semen parameters and, in some analyses, spontaneous pregnancy after antioxidant therapy in subfertile men. A recent expert-consensus guideline on SDF cites a systematic review of 45 randomized trials reporting improved spontaneous pregnancy and selected semen variables with antioxidant use, and accordingly states that antioxidants may be offered to men with high SDF, particularly when oxidative-risk factors such as smoking, obesity, toxic exposures, or advanced paternal age are present. Yet the same guideline also emphasizes that the evidence for live birth and miscarriage outcomes remains controversial, and that there is no consensus on regimen, dose, or duration.

More caution is warranted than many clinics currently show. The 2022 Cochrane review concluded that antioxidants may improve live birth or clinical pregnancy in subfertile couples, but the certainty of evidence was low because many included studies were small and methodologically limited.[50] More importantly, the large 2025 SUMMER randomized clinical trial found no improvement in ongoing pregnancy, semen parameters, fertilization or embryo-utilization outcomes, or SDF with a combined antioxidant supplement, and the investigators did not support routine use of that formulation in men seeking fertility care.[51] The trial also raised the possibility of reductive stress in unselected patients, which is especially relevant in a field that often treats antioxidants as harmless by default.

That is why empiricism should give way to selection. A recently published expert-consensus antioxidant guideline explicitly urges clinicians to document OS and consider underlying factors before starting antioxidant therapy, cautions against indiscriminate or prolonged use, and notes that treatment beyond 3-6 months is not recommended without evidence of elevated ROS.[52] In varicocele, therefore, antioxidants may have a role as adjuncts in men with demonstrable oxidative-SDF phenotypes, especially when risk factors persist after surgery or while awaiting definitive treatment, but they should not be framed as universally effective or biologically risk-free. Precision redox management requires knowing who is oxidatively burdened, not merely assuming that every infertile male is.

ART-oriented strategies in persistent high-SDF states

When elevated SDF persists despite correction of obvious causes, including varicocele repair where indicated, management often shifts from etiologic treatment to sperm-selection strategy. This is the setting in which precision management becomes particularly relevant. The EAU guideline recognizes SDF testing in couples with recurrent pregnancy loss, failed ART, or unexplained infertility, and recent reviews emphasize that persistent SDF after varicocelectomy should not be dismissed simply because conventional semen parameters improve.[2, 6] A recent expert-consensus guideline on SDF goes further by recommending repeat SDF assessment in men with persistent infertility after varicocele repair, regardless of improvement in routine semen analysis. That recommendation reflects an important clinical principle: improvement in conventional semen parameters does not

necessarily indicate restoration of underlying sperm biological integrity.[3, 36]

At the ART level, several sperm-selection methods have been explored, including physiologic ICSI, magnetic sorting, and microfluidic cell sorting. A recent expert-consensus guideline notes that these approaches can reduce the proportion of highly DNA-damaged sperm but also states that there are no convincing outcome studies demonstrating a fertility benefit specifically when they are used for elevated SDF. Accordingly, these techniques may be considered reasonable adjuncts, but they should not be presented as definitively evidence-based solutions.

The most debated step is use of testicular rather than ejaculated sperm for ICSI in nonazoospermic men with persistently high SDF. AUA/ASRM guidance now states that clinicians may consider testicular sperm in nonazoospermic males with an elevated DFI, while the EAU notes meta-analytic signals suggesting possible benefit but also highlights substantial heterogeneity. A recent systematic review likewise concluded that testicular sperm may improve ICSI outcomes in such men, but emphasized the lack of high-quality data.[53] A recent expert-consensus guideline therefore adopts a balanced position: testicular sperm should not be used routinely for elevated SDF, but may be considered after potential causes have been addressed, particularly in the setting of ART failure, with full disclosure that the supporting evidence is of low quality. In varicocele-associated infertility, that sequence is crucial. Where feasible, ART should be considered after correction of reversible biological contributors rather than as an immediate substitute for such management.

Follow-up strategy

Follow-up after treatment of varicocele-associated oxidative-SDF burden should be structured around biology rather than impatience. Because one full spermatogenic cycle requires roughly 72 days, reassessment too early risks measuring sperm that matured under the old pathological environment rather than under the benefit of intervention. The 2024 varicocele-focused review by Lira et al. notes that most authors recommend repeat SDF testing between 3 and 6 months after varicocelectomy, paralleling the usual timetable for repeat semen analysis. Some studies suggest progressive SDF decline with longer follow-up, whereas others show an early postoperative improvement that then plateaus, but the common message is that molecular reassessment should not precede biological renewal.

A rational follow-up pathway therefore includes, first, reassessment of conventional semen parameters at about 3 months, with extension to 6 months when clinical circumstances permit. Second, repeat SDF testing should be considered in men whose pre-treatment SDF was elevated, in those with persistent infertility despite improved semen results, or in those with recurrent pregnancy loss or ART failure where management decisions may change according to whether genomic injury has actually improved. The GAF guideline specifically recommends SDF testing in men with persistent infertility after varicocele repair, regardless of apparent improvement in standard semen analysis, underscoring that routine parameters alone are not sufficient follow-up endpoints in every case.

Third, follow-up should not end with laboratory normalization. The meaningful endpoint is reproductive trajectory: time-to-pregnancy, need for ART escalation, and whether modifiable oxidative drivers remain active. Men with persistent high SDF after surgery require reappraisal of smoking status, obesity, inflammation, abstinence pattern, occupational heat, and other co-drivers before moving reflexively to invasive ART strategies. If SDF remains elevated despite that broader correction, ART-oriented sperm selection or testicular sperm may then become reasonable discussion points. In other words, follow-up is not a single postoperative laboratory check; it is a staged decision process that asks whether the lesion was corrected, whether the biology improved, and whether the couple's reproductive path has truly changed.

A PRECISION MANAGEMENT FRAMEWORK FOR VARICOCELE-ASSOCIATED MALE INFERTILITY

Proposed clinical algorithm

A precision framework for varicocele-associated male infertility should begin with recognition that not all palpable varicoceles are biologically equivalent. The first step remains conventional: confirm infertile couple status, define female-partner time sensitivity, document a palpable varicocele, and obtain at least one properly performed semen analysis with repeat testing where indicated. This is still the foundation endorsed by both the AUA/ASRM amendment and the 2025 EAU update. However, the second step is the critical one: determine whether the clinical phenotype is adequately explained by routine semen abnormalities alone, or whether there is discordance between the visible lesion, the couple history, and laboratory findings. Such discordance includes prolonged infertility despite only mild semen changes, recurrent pregnancy loss, failed ART, or apparent semen improvement after repair without reproductive progress. In these situations, selective escalation to SDF testing becomes both biologically and clinically justified rather than merely discretionary.[1, 2, 38]

The third step is phenotypic assignment (**Table 2**). Men can then be classified broadly into semen-predominant disease, oxidative-SDF predominant disease, or mixed phenotypes with coexisting inflammatory, mitochondrial, or lifestyle-metabolic amplifiers.[54] The fourth step is treatment sequencing: conventional candidates proceed to varicocelectomy when guideline criteria are met; discordant high-SDF phenotypes may justify repair even when routine semen data understate severity; and mixed phenotypes require combined correction of varicocele plus modifiable oxidative drivers. The final step is reassessment after a biologically reasonable interval, usually aligned with a spermatogenic cycle, because biomarker normalization and reproductive success are not immediate or interchangeable outcomes. The central principle is that anatomy initiates evaluation, whereas biology determines the intensity and direction of management.[2, 6]

Candidate phenotypes for precision care

Not every infertile man with varicocele needs the same intervention, and this is precisely where a precision framework adds value. The first phenotype is the *classical semen-predominant phenotype*: palpable varicocele, infertility, and abnormal semen

Table 2. Precision management matrix in varicocele-associated male infertility: phenotype-directed evaluation, intervention, and follow-up endpoints.

Clinical phenotype	Typical clinical scenario	First-line evaluation	Second-line / adjunctive tests	Most rational management strategy	Follow-up endpoints	References
Classical semen-predominant phenotype	Palpable varicocele, infertility, clearly abnormal semen parameters	History, physical examination, semen analysis, couple evaluation	Hormonal profile where indicated	Varicocelectomy according to guideline criteria	Semen improvement; natural conception; time-to-pregnancy	Brannigan et al., 2024; Minhas et al., 2025
Discordant genomic phenotype	Palpable varicocele with prolonged infertility, recurrent pregnancy loss, failed ART, or poor embryo progression despite mild / near-normal semen	Standard male infertility work-up	SDF testing (TUNEL/SCSA/SCD/Comet); selected OS assessment	Consider repair despite modest routine semen abnormality; intensify counseling and reproductive planning	SDF reduction; pregnancy trajectory; miscarriage reduction	Lira et al., 2024; Çayan et al., 2025; Palani et al., 2025
Oxidative-inflammatory phenotype	Varicocele plus smoking, obesity, genital tract inflammation, heat exposure, metabolic dysfunction, or other oxidative amplifiers	Standard work-up plus exposure / lifestyle history	SDF ± OS markers; inflammatory assessment where relevant	Varicocelectomy plus correction of oxidative co-drivers; selected antioxidant use only in appropriate phenotype	Semen profile; SDF; oxidative burden; symptom / exposure control	Szabó et al., 2023; Szabó et al., 2025; Agarwal et al., 2026
High-SDF varicocele with otherwise unexplained infertility	Palpable varicocele, infertility not adequately explained by female or male routine factors, raised SDF	Couple work-up; semen analysis	SDF testing as key escalation step	Consider varicocelectomy in selected cases; phenotype-based counseling	SDF reduction; natural conception; ART avoidance or delay	Minhas et al., 2025; Çayan et al., 2025; Almekaty et al., 2025
Persistent post-repair genomic phenotype	Post-varicocelectomy improvement in semen, but persistent infertility and/or persistently elevated SDF	Repeat semen analysis at 3–6 months	Repeat SDF testing; reassessment of oxidative exposures	Reappraise smoking, obesity, heat, inflammation, abstinence pattern; selective ART-oriented escalation	Persistent vs improved SDF; time-to-pregnancy; need for ART	Lira et al., 2024; Çayan et al., 2025
ART-failure phenotype with varicocele biology	Prior IVF/ICSI failure, implantation failure, or recurrent pregnancy loss in the setting of palpable varicocele	Standard infertility reassessment	SDF testing; selective adjunctive testing	Correct reversible biology first; then consider sperm-selection strategies or testicular sperm in highly selected nonazoospermic men	Clinical pregnancy; miscarriage; live birth; ART efficiency	Minhas et al., 2025; Khoo et al., 2024; Wan et al., 2026
Non-palpable / subclinical varicocele phenotype	Imaging-only varicocele without clear clinical correlate	Standard infertility work-up	Molecular testing only if compelling phenotype and evidence gap acknowledged	Usually conservative management; avoid reflex repair	Observation; phenotype evolution	Brannigan et al., 2024; Minhas et al., 2025
Research / future precision-endotyping phenotype	Men with discordant biology or persistent "idiopathic" infertility after standard evaluation	Standard work-up	Integrated OS + SDF + mitochondrial / inflammatory / epigenetic profiling	Research-oriented molecular phenotyping; potential reclassification of idiopathic infertility	Biomarker-defined endotype; phenotype-linked treatment response	Kaltsas et al., 2026; Sengupta et al., 2026

parameters without major diagnostic ambiguity. This remains the clearest surgical candidate under current AUA/ASRM and EAU guidance. The second is the *discordant genomic phenotype*, in which semen analysis is normal or only mildly abnormal, yet the couple history suggests biologically important male-factor disease, typically recurrent pregnancy loss, unexplained infertility, repeated implantation failure, or prior ART inefficiency. Here, SDF testing is most likely to reveal clinically meaningful hidden damage and to alter treatment sequencing. Both recent guideline-era reviews and contemporary expert-consensus recommendations support considering SDF in these contexts rather than as a universal screening test.[1, 2, 38]

A third group is the *oxidative-inflammatory phenotype*, where varicocele coexists with smoking, obesity, genital tract inflammation, heat exposure, metabolic dysfunction, or other oxidative amplifiers. In such men, surgery alone may underperform

unless the surrounding redox ecology is also corrected. A fourth is the *persistent post-repair phenotype*, characterized by continued infertility or elevated SDF after technically successful repair. These men are the clearest examples of why precision management cannot end with surgery: they may require renewed exposure correction, reassessment of SDF, and selective ART-oriented strategies. This phenotype-based reading is strongly consistent with recent varicocele-focused literature, which argues that the lesion should be interpreted not merely by grade or ultrasound appearance, but by the biological pattern it expresses, semen-predominant, oxidative-genomic, or mixed.[6, 9]

Proposed outcomes to track

A precision framework is only useful if it measures the right endpoints. In varicocele-associated infertility, the most common error is to treat postoperative semen improvement as the sole definition of success. Semen concentration, motility, morphology, and vitality remain important and should be tracked, but they are only the first layer. In men with elevated baseline SDF, genomic improvement should be considered a parallel endpoint, particularly when the original indication for expanded testing was recurrent pregnancy loss, unexplained infertility, or ART failure. Recent evidence shows that varicocele repair can reduce SDF and markers of oxidative injury, which makes SDF a legitimate response biomarker in selected men rather than a static diagnostic label.[6, 8]

The second layer of outcomes should be couple-centered rather than laboratory-centered. These include natural conception rate, time-to-pregnancy, clinical pregnancy after ART, miscarriage rate, and progression to more invasive reproductive interventions. The reason is straightforward: a molecularly improved semen sample is clinically meaningful only if it alters reproductive trajectory. Contemporary SDF guidelines and the 2025 EAU update both reinforce this broader view by linking SDF relevance not only to semen quality, but to recurrent pregnancy loss, ART inefficiency, and post-repair reassessment in selected patients.[2, 38]

The final outcome domain is strategic: whether management escalation was avoided, delayed, or refined. A successful precision pathway may mean natural conception after repair, avoidance of unnecessary empiric antioxidants, or more rational use of ART when persistent high-SDF biology remains despite treatment. Thus, the optimal endpoint is not ‘better semen’ in isolation, but measurable movement from biological dysfunction toward reproductive efficiency.

CONTROVERSIES AND UNRESOLVED QUESTIONS

Assay standardization

One of the central unresolved problems in this field is that neither OS testing nor SDF testing is methodologically uniform enough to support a single universal diagnostic language. TUNEL, sperm chromatin structure assay, Comet, and sperm chromatin dispersion do not measure identical forms of DNA injury, and their reported thresholds are not interchangeable. The 2025 EAU update explicitly notes that current methods of assessing sperm DNA integrity still do not reliably predict ART outcomes, which is a concise summary of the standardization problem: the assays are clinically informative, but not yet sufficiently harmonized to function as a universal triage tool.[2] A recent expert-consensus guideline reaches a similar conclusion, supporting assay-specific interpretation and selective use rather than indiscriminate screening.[38]

The same concern applies to OS biomarkers. Direct ROS assays, MDA, TAC, and ORP interrogate different parts of redox biology, yet they are often discussed as if they were interchangeable proxi for a single construct. Recent reviews continue to argue for combined OS and SDF testing in selected varicocele phenotypes, but that proposal itself reflects the incompleteness of any one assay in isolation.[42] Until inter-laboratory reproducibility, assay calibration, and phenotype-linked thresholds are better defined, the field will remain vulnerable to overinterpretation of laboratory numbers that look precise but are not yet universally commensurable.

Cause versus correlation

A second controversy is whether OS and SDF are true mediators of infertility in varicocele, or whether they are merely associated biomarkers riding alongside deeper causal processes. The biological case for mediation is strong: varicocele is linked to hyperthermia, microcirculatory disturbance, inflammation, and mitochondrial dysfunction, all of which plausibly drive oxidative DNA injury. Interventional evidence strengthens this argument, because varicocele repair has been associated with reductions in both SDF and oxidative damage markers, suggesting more than passive correlation.[8, 55] Yet even this does not fully settle causality, because improvement in biomarkers after surgery does not prove that those biomarkers are the principal pathway through which fertility improves.

The uncertainty is not trivial. Some men with varicocele and elevated SDF remain fertile, whereas others with modest or borderline SDF still experience infertility or miscarriage. This implies that SDF may be one important mediator among several, rather than the sole biologic determinant. The 2025 varicocele-SDF meta-analysis supports a robust association between varicocele and elevated SDF, but association alone cannot define how much of the lesion’s reproductive effect is actually transmitted through genomic injury as opposed to endocrine, mitochondrial, epigenetic, or broader seminal-plasma alterations.[9] In practical terms, the field still lacks definitive prospective models showing how much SDF reduction is necessary, or sufficient, to shift time-to-pregnancy or live birth in a predictable way.

Clinical threshold problem

Even when clinicians accept that SDF is relevant, the next question remains unsettled: at what level should it actually change management? This is the threshold problem. Different assays generate different numeric ranges, and studies often use cutoffs that are test-specific, laboratory-specific, or derived from heterogeneous infertility populations rather than varicocele-enriched cohorts. The 2026 Global Andrology Forum guideline endorses selective SDF testing and clinical integration, but it does not reduce decision-making to a single universal threshold; that omission is not a weakness of the guideline, but an accurate reflection of the evidence base.[38] The 2025 EAU update is similarly cautious, recognizing SDF as clinically relevant in selected scenarios while stopping short of endorsing any absolute decision threshold for repair or ART escalation.[2]

This ambiguity affects real clinical choices. Should a man with palpable varicocele, mild semen abnormality, and moderately elevated SDF proceed to surgery before ART? Should a couple with recurrent pregnancy loss and a borderline-high DFI be counseled toward repair, antioxidant therapy, shorter abstinence, or direct ICSI? Without validated outcome-linked thresholds, management remains probabilistic. Recent expert reviews have argued that the answer lies less in a single cutoff than in phenotype-dependent interpretation: female age, infertility duration, prior ART failure, and coexisting oxidative exposures may matter as much as the measured SDF value itself.[35, 42] The unresolved issue, therefore, is not simply 'what threshold is high', but 'high for whom, in which assay, and in what reproductive context?'

Role of subclinical varicocele

The role of subclinical varicocele remains one of the most persistent gray zones in andrology. Current mainstream guidance continues to distinguish sharply between palpable clinical varicocele and lesions identified only by imaging. The AUA/ASRM framework has long advised against repair of non-palpable varicoceles detected solely on imaging, and the broader 2025 EAU update remains aligned with the principle that treatment recommendations are centered on clinically evident disease rather than ultrasound abnormalities alone.[2] This stance is grounded in the concern that imaging can identify venous dilatation without proving that the lesion is biologically active or causally relevant to infertility.

Yet the counterargument has not disappeared. If varicocele is truly a biological rather than purely anatomical disease, then it is theoretically possible for some subclinical lesions to carry meaningful oxidative or genomic consequences. The problem is that the evidence base remains too thin and too inconsistent to identify which, if any, of these men would benefit from intervention. Most of the stronger data on SDF, OS, and postoperative improvement come from cohorts with clinical varicocele.[6] As a result, extending these insights to subclinical disease risks overreach. For now, the unresolved question is not whether subclinical varicocele can ever be biologically relevant, but whether the field can define a subgroup in whom imaging-only lesions genuinely behave like clinical disease rather than incidental anatomy. That subgroup, if it exists, has not yet been convincingly mapped.

Antioxidants after varicocelectomy

Whether antioxidants should be routinely prescribed after varicocelectomy remains unsettled. The theoretical rationale is attractive: if surgery reduces the upstream venous driver but residual oxidative injury persists during recovery, adjunctive antioxidants might accelerate normalization of sperm function and DNA integrity. Some recent literature continues to support antioxidant use in selected high-SDF or oxidative-stress phenotypes, and comparative syntheses have evaluated antioxidant therapy alongside varicocelectomy as a potentially useful intervention for sperm DNA damage.[49] But this logic is not equivalent to proof of postoperative benefit.

The unresolved issue is selection. If varicocelectomy has already lowered oxidative burden, indiscriminate antioxidant therapy may add little and could, in theory, push some men toward reductive imbalance. Contemporary guideline thinking has become more cautious on precisely this point: antioxidant therapy is increasingly framed as potentially useful in selected men with documented oxidative risk rather than as a universal add-on. The question is therefore not 'do antioxidants work?' in the abstract, but 'which post-varicocelectomy patients retain a demonstrable redox burden that justifies adjunctive treatment?' At present, the field lacks adequately powered phenotype-stratified trials comparing surgery alone with surgery plus biomarker-guided antioxidant therapy. Until those data exist, postoperative antioxidant use remains a biologically plausible but incompletely resolved strategy.

FUTURE DIRECTIONS

The next phase of varicocele research should move beyond descriptive associations and build a biologically stratified clinical science. Three priorities are especially pressing. First, the field needs integrated phenotyping, not isolated biomarkers. Recent reviews increasingly argue that OS and SDF should be interpreted as complementary rather than competing readouts, and that future models should incorporate redox biomarkers, SDF, inflammatory mediators, mitochondrial function, and selected epigenetic signatures into a unified molecular profile of varicocele-associated sperm injury.[42, 54] Second, these biomarkers must be linked to standardized, outcome-based thresholds. Current guidelines acknowledge the clinical value of SDF in selected men, yet also emphasize that assay heterogeneity and insufficient interventional data still limit confident treatment algorithms.[2, 38] What is now needed are prospective, assay-specific studies that define which molecular phenotypes predict benefit from varicocelectomy, adjunctive antioxidant therapy, or ART escalation. Third, future trials should abandon semen improvement as the sole endpoint. Varicocele repair may reduce oxidative injury and SDF, but the clinically meaningful questions are whether these changes shorten time-to-pregnancy, reduce miscarriage, improve live birth, and prevent unnecessary ART.[6, 8] Enrichment designs focused on men with high-SDF or oxidative-inflammatory phenotypes are likely to be more informative than heterogeneous all-comer cohorts. Finally, multi-omic and mechanistic studies should be used not merely to generate biomarkers, but to reclassify part of 'idiopathic' male infertility into biologically coherent subgroups. That shift, from venous anatomy to molecular endotyping, will determine whether varicocele management remains empiric or becomes genuinely precise.[56]

CONCLUSIONS

Varicocele should no longer be interpreted as a merely dilated venous plexus assessed only by palpation, grade, and routine semen analysis. The stronger contemporary view is biological: varicocele can function as a redox-inflammatory stress lesion that destabilizes sperm function and compromises paternal genome integrity, with SDF serving as one of its most clinically meaningful downstream expressions. This framework helps explain why fertility impairment may be substantial even when conventional semen abnormalities appear modest, and why varicocele repair may have value beyond numerical improvement in count or motility alone.[6, 9] The practical implication is a shift from anatomy-based treatment

to phenotype-guided management. Current guideline-era evidence supports repair primarily in infertile men with palpable varicocele and abnormal semen parameters, while also opening the door to more selective use of SDF-informed decision-making in otherwise unexplained infertility, recurrent pregnancy loss, and prior ART failure.[2] Varicocelectomy appears capable of reducing oxidative damage markers and SDF in selected men, but important uncertainties remain regarding assay standardization, thresholds for intervention, and the degree to which biomarker improvement translates into live birth benefit.[2, 8] Accordingly, the future of this field lies in precision andrology: integrating clinical varicocele phenotype with OS, SDF, and couple-level reproductive context to identify which men truly harbor biologically active disease and which intervention is most likely to change outcome.

REFERENCES

1. R.E. Brannigan, L. Hermanson, J. Kaczmarek, S.K. Kim, E. Kirkby, C. Tanrikut. Updates to male infertility: AUA/ASRM guideline (2024). *The Journal of urology* **2024**, 212(6), 789-99.
2. Minhas S, Boeri L, Capogrosso P, Cocci A, Corona G, Dinkelman-Smit M, et al. European Association of Urology Guidelines on Male Sexual and Reproductive Health: 2025 Update on Male Infertility. *European Urology* **2025**, 87(5), 601-16.
3. A. Agarwal, A. Majzoub, S. Baskaran, M.K.P. Selvam, C.L. Cho, R. Henkel, et al. Sperm DNA fragmentation: a new guideline for clinicians. *The world journal of men's health* **2020**, 38(4), 412.
4. S.C. Esteves, A. Zini, R.M. Coward, D.P. Evenson, J. Gosálvez, S.E. Lewis, et al. Sperm DNA fragmentation testing: Summary evidence and clinical practice recommendations. *Andrologia* **2021**, 53(2), e13874.
5. G.J.A. Wood, J.P.G. Cardoso, D.V. Paluello, T.F. Nunes, M. Cocuzza. Varicocele-associated infertility and the role of oxidative stress on sperm DNA fragmentation. *Frontiers in reproductive health* **2021**, 3, 695992.
6. F.T. Lira, L.R. Campos, M. Roque, S.C. Esteves. From pathophysiology to practice: addressing oxidative stress and sperm DNA fragmentation in Varicocele-affected subfertile men. *International braz j urol* **2024**, 50(5), 530-60.
7. P. Sengupta, S. Roychoudhury, M. Nath, S. Dutta. Oxidative stress and idiopathic male infertility. *Oxidative stress and toxicity in reproductive biology and medicine: a comprehensive update on male infertility-volume one* **2022**, 181-204.
8. R. Cannarella, R. Shah, R. Saleh, F. Boitrelle, T.A.-A.A.-M. Hamoda, R. Singh, et al. Effects of varicocele repair on sperm DNA fragmentation and seminal malondialdehyde levels in infertile men with clinical varicocele: a systematic review and meta-analysis. *The world journal of men's health* **2024**, 42(2), 321.
9. A. Palani, S. Çayan, R. Cannarella, R. Saleh, B. Altay, M. Kadihasanoglu, et al. Sperm DNA Fragmentation in Men with Varicocele: A Systematic Review and Meta-Analysis. *The World Journal of Men's Health* **2025**, 43.
10. B. Alsaikhan, K. Alrabeeah, G. Delouya, A. Zini. Epidemiology of varicocele. *Asian journal of andrology* **2016**, 18(2), 179-81.
11. D.K. Kim, D.S. Kim, S.C. Kam, H.S. Lee, W.K. Lee, S.-H. Song. Recent guidelines and perspectives for varicocele: a clinical consensus and recommendations from the Korean Society for Sexual Medicine and andrology. *The World Journal of Men's Health* **2025**, 43(4), 748.
12. M.A. Ogunjimi, O.A.-R. Abudu, E.A. Jeje, R.W. Ojewola, R.A. Arogundade. A prospective study of the association between varicoceles and semen quality in men with infertility. *African Journal of Urology* **2024**, 30(1), 50.
13. R.G. Bissette, M.P. Edelson, K.J. Campbell, C.E. Bayne. Diagnosis and Management of Pediatric Varicocele: A Modern Update for the Practicing Pediatrician. *Current Treatment Options in Pediatrics* **2024**, 11(1), 5.
14. C. Munoz-Lopez, A. Wong, K. Lewis, R. Bole, S.C. Vij, S.D. Lundy. The evolving landscape of male varicocele pathophysiology in the era of multi-omics: a narrative review of the current literature. *Biology* **2024**, 13(2), 80.
15. L.-H. Wang, L. Zheng, H. Jiang, T. Jiang. Research advances in inflammation and oxidative stress in varicocele-induced male infertility: a narrative review. *Asian Journal of Andrology* **2025**, 27(2), 177-84.
16. G.I. Russo, R. Saleh, F. Finocchi, A.R. Juma, D. Durairajanayagam, O. Kahraman, et al. Impact of varicocele on testicular oxidative stress and sperm parameters in experimental animals: a systematic review and meta-analysis. *The world journal of men's health* **2024**, 42(3), 563.
17. K. Wang, Y. Gao, C. Wang, M. Liang, Y. Liao, K. Hu. Role of oxidative stress in varicocele. *Frontiers in Genetics* **2022**, 13, 850114.
18. A. Crafa, R. Cannarella, R.A. Condorelli, L.M. Mongioì, S. La Vignera, A.E. Calogero. Predictive parameters of the efficacy of varicocele repair: a review. *Asian journal of andrology* **2024**, 26(5), 441-50.
19. A. Kaltsas, A. Zikopoulos, E. Markou, A. Zachariou, M. Stavropoulos, Z. Kratiras, et al. Proteomics and metabolomics in varicocele-associated male infertility: Advancing precision diagnostics and therapy. *Journal of Clinical Medicine* **2024**, 13(23), 7390.
20. J. Aitken, H. Fisher. Reactive oxygen species generation and human spermatozoa: the balance of benefit and risk. *Bioessays* **1994**, 16(4), 259-67.
21. E. De Lamirande, C. Gagnon. Reactive oxygen species and human spermatozoa: I. Effects on the motility of intact spermatozoa and on sperm axonemes. *Journal of andrology* **1992**, 13(5), 368-78.
22. S.S. Du Plessis, A. Agarwal, J. Halabi, E. Tvrda. Contemporary evidence on the physiological role of reactive oxygen species in human sperm function. *Journal of assisted reproduction and genetics* **2015**, 32(4), 509-20.
23. S. Dutta, A. Majzoub, A. Agarwal. Oxidative stress and sperm function: A systematic review on evaluation and management. *Arab journal of urology* **2019**, 17(2), 87-97.
24. E.N. Symeonidis, E. Evgeni, V. Palapelas, D. Koumasi, N. Pyrgidis, I. Sokolakis, et al. Redox balance in male infertility: Excellence through moderation-"Μέτρον ἄριστον". *Antioxidants* **2021**, 10(10), 1534.
25. P. Sengupta, G.M. Pinggera, A.E. Calogero, A. Agarwal. Oxidative stress affects sperm health and fertility-Time to apply facts learned at the bench to help the patient: Lessons for busy clinicians. *Reproductive Medicine and Biology* **2024**, 23(1), e12598.
26. C. Ritchie, E.Y. Ko. Oxidative stress in the pathophysiology of male infertility. *Andrologia* **2021**, 53(1), e13581.
27. C. Wright, S. Milne, H. Leeson. Sperm DNA damage caused by oxidative stress: modifiable clinical, lifestyle and nutritional factors in male infertility. *Reproductive biomedicine online* **2014**, 28(6), 684-703.
28. E.A.o.U. (EAU). EAU Guidelines on Sexual and Reproductive Health: Male Infertility chapter. 2025.
29. P.E. Castleton, J.C. Deluao, D.J. Sharkey, N.O. McPherson. Measuring reactive oxygen species in semen for male preconception care: a scientist perspective. *Antioxidants* **2022**, 11(2), 264.
30. F. Mottola, I. Palmieri, M. Carannante, A. Barretta, S. Roychoudhury, L. Rocco. Oxidative stress biomarkers in male infertility: Established methodologies and future perspectives. *Genes* **2024**, 15(5), 539.
31. M. Gholinezhad, A. Aliarab, G. Abbaszadeh-Goudarzi, Y. Yousefnia-Pasha, N. Samadaian, K. Rasolpour-Roshan, et al. Nitric oxide, 8-hydroxydeoxyguanosine, and total antioxidant capacity in human seminal plasma of infertile men and their relationship with sperm parameters. *Clinical and experimental reproductive medicine* **2020**, 47(1), 54.
32. A. Agarwal, M.K.P. Selvam, M. Arafa, H. Okada, S. Homa, A. Killeen, et al. Multi-center evaluation of oxidation-reduction potential by the MiOXSYS in males with abnormal semen. *Asian Journal of Andrology* **2019**, 21(6), 565-9.
33. T.P. Furtado, V. Osadchiy, M.H. Furtado. Semen static oxidation–reduction potential is not helpful in evaluating male fertility. *Andrology* **2025**, 13(6), 1432-8.
34. S.W. Andrabi, A. Ara, A. Saharan, M. Jaffar, N. Gugnani, S.C. Esteves. Sperm DNA Fragmentation: causes, evaluation and management in male infertility. *JBRA assisted reproduction* **2024**, 28(2), 306.
35. S.C. Esteves. From Double Helix to Double Trouble: Sperm DNA Fragmentation Unveiled–A Reproductive Urologist Perspective (AUA

Bruce Stewart Memorial Lecture–ASRM 2024). SciELO Brasil; 2025. p. e20249924.
36. A. Agarwal, A.a. Farkouh, N. Parekh, A. Zini, M. Arafa, H. Kandil, et al. Sperm DNA fragmentation: a critical assessment of clinical practice guidelines. *The world journal of men's health* **2021**, 40(1), 30.
37. P. Sengupta, S. Dutta, A.V. Samrot. Sperm DNA fragmentation testing in infertility. Genetic Testing in Reproductive Medicine: Springer; 2024. p. 47-66.
38. S. Çayan, A.a. Farkouh, A. Agarwal, W. Atmoko, C. Wyns, M. Arafa, et al. Global Andrology Forum clinical guidelines on the relevance of sperm DNA fragmentation in reproductive medicine. *The world journal of men's health* **2025**, 44(1), 78.
39. S. Dutta, A. Biswas, P. Sengupta. Obesity, endocrine disruption and male infertility. *Asian Pacific Journal of Reproduction* **2019**, 8(5), 195-202.
40. K. Bhattacharya, P. Sengupta, S. Dutta, I.R. Karkada. Obesity, systemic inflammation and male infertility. *Chemical Biology Letters* **2020**, 7(2), 92-8.
41. P. Sengupta, S. Dutta, A.T. Alahmar. Reproductive tract infection, inflammation and male infertility. *Chemical Biology Letters* **2020**, 7(2), 75-84.
42. A. Kaltsas, S. Papaharitou, P. Sengupta, R. Saleh, A. Agarwal. Oxidative Stress, Sperm DNA Fragmentation, or Both? Optimizing Test Selection in Male Infertility Evaluation. *Antioxidants* **2026**, 15(3), 293.
43. B. Wan, Y. Fu, N. Ma, Z. Zhou, W. Lu. Sperm DNA fragmentation and assisted reproduction: an umbrella meta-analysis. *European Journal of Medical Research* **2026**, 31(1), 218.
44. F. Li, X. Duan, M. Li, X. Ma. Sperm DNA fragmentation index affect pregnancy outcomes and offspring safety in assisted reproductive technology. *Scientific Reports* **2024**, 14(1), 356.
45. A. Szabó, S. Váncsa, P. Hegyi, T. Kói, J. Ács, R.J. Hermánné, et al. Assessing the efficacy of varicocelectomy, antioxidants, FSH treatment, and lifestyle modifications on sperm DNA fragmentation: a systematic review and meta-analysis. *Scientific reports* **2025**, 15(1), 10118.
46. P. Sengupta, K. Bhattacharya, S. Dutta. Leptin and male reproduction. *Asian Pacific Journal of Reproduction* **2019**, 8(5), 220-6.
47. T. Irez, S. Bicer, E. Sahin, S. Dutta, P. Sengupta. Cytokines and adipokines in the regulation of spermatogenesis and semen quality. *Chemical Biology Letters* **2020**, 7(2), 131-9.
48. M.K. Panner Selvam, P. Sengupta, A. Agarwal. Sperm DNA fragmentation and male infertility. Genetics of male infertility: a case-based guide for clinicians: Springer; 2020. p. 155-72.
49. A. Szabó, S. Vancsa, P. Hegyi, A. Varadi, A. Forintos, T. Filipov, et al. Lifestyle-, environmental-, and additional health factors associated with an increased sperm DNA fragmentation: a systematic review and meta-analysis. *Reproductive Biology and Endocrinology* **2023**, 21(1), 5.
50. W. de Ligny, R.M. Smits, R. Mackenzie-Proctor, V. Jordan, K. Fleischer, J.P. de Bruin, M.G. Showell. Antioxidants for male subfertility. *Cochrane database of systematic reviews* **2022**, (5).
51. W.R. de Ligny, J.P. de Bruin, R.M. Smits, I.G. Goovaerts, K. Peeters, A.W. Nap, et al. Antioxidant treatment and the chance to conceive in men seeking fertility care: the SUMMER randomized clinical trial. *JAMA Network Open* **2025**, 8(9), e2532405.
52. A. Agarwal, T. Mostafa, M. Al Hashimi, S. Çayan, E. Pescatori, K. Singh, et al. Global Andrology Forum Clinical Guidelines on Antioxidant Use in the Treatment of Male Infertility. *The world journal of men's health* **2026**, 44.
53. C.C. Khoo, A.A. Cayetano-Alcaraz, R. Rashid, T. Tharakan, T. Yap, N. Sofikitis, et al. Does testicular sperm improve intracytoplasmic sperm injection outcomes for nonazoospermic infertile men with elevated sperm DNA fragmentation? A systematic review and meta-analysis. *European Urology Focus* **2024**, 10(3), 410-20.
54. P. Sengupta, S. Dutta, M.A. Elsuity, R. Saleh. Redox–Genomic Crosstalk: Linking Oxidative Stress, Sperm DNA Fragmentation, and Epigenetics in Personalized Management of Male Infertility. *Journal of Personalized Medicine* **2026**, 16(2), 79.
55. K. Almekaty, A. Ghaith, M. Ragab, H. Elbardisi. Is varicocele repair justified in infertile men with clinical varicocele, normal conventional semen parameters and elevated sperm DNA fragmentation (SDF)? *Arab Journal of Urology* **2025**, 23(3), 230-6.
56. P. Sengupta, S. Dutta, R. Henkel, I.M. Rosas, S. Roychoudhury. Idiopathic male infertility revisited: can redox endophenotypes reframe the 'idiopathic'label? *Frontiers in Endocrinology* **2026**, 17, 1747453.